

## Use of light emitting diode (LED) in the healing of burns: systematic review of the literature

## Utilização do diodo emissor de luz (LED) na cicatrização de queimaduras: revisão sistemática da literatura

Marlise de Jesus Santos Araújo<sup>1</sup>, Gabriela Botelho Martins<sup>2</sup>

<sup>1</sup>Federal University of Bahia. Salvador, Bahia, Brazil. ORCID: 0000-0002-0169-5102. marlise-araujo@hotmail.com

<sup>2</sup>Corresponding author. Federal University of Bahia. Salvador, Bahia, Brazil. ORCID: 0000-0002-0917-4598. gbmartinsba@gmail.com

**RESUMO | INTRODUÇÃO:** O tratamento de vítimas de queimadura é desafiador pela gravidade da própria lesão e das complicações que podem ocorrer durante o processo de cicatrização. A fisioterapia dermatofuncional tem atuação no tratamento de cicatrizes, utilizando de terapias para acelerar o processo cicatricial e recuperação funcional adequada. O diodo emissor de luz ou LED tem sido descrita como uma possibilidade terapêutica valiosa para fisioterapia com o intuito de reduzir complicações funcionais e estéticas em processos cicatriciais de indivíduos queimados. **OBJETIVOS:** Revisar a literatura acerca da utilização da luz LED e seus efeitos na cicatrização tecidual na lesão por queimadura. **MATERIAIS E MÉTODOS:** Trata-se de uma revisão sistemática da literatura, realizada no mês de agosto de 2017, utilizando as bases de dados Bireme, PubMed e PeDro, baseado nos critérios PRISMA. Foram incluídos no estudo os artigos que abordassem a utilização do LED na cicatrização específica de queimaduras, publicados nos últimos cinco anos (2012 -2017), nos idiomas inglês e português. Os critérios de exclusão foram artigos que abordaram o uso do LED na cicatrização tecidual em geral. A seleção dos artigos foi realizada por dois autores, não havendo consenso entre ambos, um terceiro autor seria convocado, o que não foi necessário nesta busca. **RESULTADOS:** Foram encontrados 1.029 artigos na busca, destes foram incluídos 04 artigos, que abordaram a utilização do LED na cicatrização específica de queimaduras publicados de 2012 a 2017. Todos os estudos encontraram melhoras do processo cicatricial com uso do LED, mesmo sendo utilizados comprimentos de onda distintos nos trabalhos analisados. **CONCLUSÃO:** A utilização do LED no tratamento de queimaduras demonstrou favorecer o processo de cicatrização tecidual em animais e melhorar os aspectos histológicos nos tecidos tratados, porém ainda pouco utilizado na Fisioterapia.

**PALAVRAS-CHAVE:** Fisioterapia. Fototerapia. Queimaduras. Laser de diodo.

**ABSTRACT | INTRODUCTION:** The treatment of burn victims is challenging because of the severity of the lesion itself and the complications that may occur during the healing process. Dermatofunctional physiotherapy works in the treatment of scars, using therapies to accelerate the cicatricial process and adequate functional recovery. The light emitting diode or LED has been described as a valuable therapeutic possibility for physiotherapy with the aim of reducing functional and aesthetic complications in the cicatricial processes of burned individuals. **OBJECTIVES:** To review the literature on the use of LED light and its effects on tissue healing in burn injury. **MATERIALS AND METHODS:** This is a systematic review of the literature, conducted in August 2017, using the Bireme, PubMed and PeDro databases, based on PRISMA criteria. The study included articles that addressed the use of LED in the specific healing of burns, published in the last five years (2012 -2017), in the English and Portuguese languages. The exclusion criteria were articles that addressed the use of LED in tissue healing in general. The selection of articles was carried out by two authors, and there was no consensus between the two, a third author would be called, which was not necessary in this search. **RESULTS:** A total of 1,029 articles were found in the search, of which 04 articles were included, which addressed the use of LEDs in the specific cicatrization of burns published from 2012 to 2017. All studies found improvements of the cicatricial process using LED, even though different wavelengths were used in the analyzed works. **CONCLUSION:** The use of LED in the treatment of burns has favored the healing process in animals and improve the histological aspects in the treated tissues, but still little used in physiotherapy.

**KEYWORDS:** Physiotherapy. Phototherapy. Burns. Diode laser.

## Introduction

The treatment of burn victims is challenging both for the severity of the injury itself and for the complications that may occur during the healing process, which tends to occur in an anarchic way and with great potential for sequelae<sup>1</sup>. These can lead to severe functional and aesthetic impairments in the long term<sup>2,3</sup> as in the development of hypertrophic scars, keloids, and soft and / or articular contractures<sup>4</sup>.

Tissue repair involves complex processes associated with factors that can lead to difficulties in healing and result in important dysfunctions and sequelae, functionally impacting people's lives<sup>5</sup>. Dermatologic-functional physiotherapy has a role in the treatment of post-burn scars, using therapies to accelerate the cicatricle process and adequate functional recovery of injured tissue<sup>6</sup>.

Therapies that use less invasive, non-medicated procedures that promote reduction of complications, improve aesthetics and minimize scarring deformities after injury have been the subject of studies, such as Light Emitting Diode or LED<sup>5,7,8</sup>. Its applicability has been studied in recent years to obtain positive bio modulators results in tissue healing<sup>5,8,9</sup>.

The LED has been described as a valuable therapeutic possibility for physiotherapy with the aim of reducing functional and aesthetic complications in cicatricle processes<sup>5</sup>, including individuals who are victims of burns<sup>6</sup>. This is because LED light is used as a non-coherent source of light, presenting a mechanism of action similar to low power laser (LPL), making it a cheaper possibility in clinical practice when seeking improvement in cicatricle processes<sup>5,9</sup>.

Moura et al.<sup>8</sup> in a systematic review (2014) on the effects of LED light on wound healing have described from other authors that the emission of light by diodes acts favoring the increase of cellular proliferation, stimulating the local circulation, contributing to improve the production and deposition of collagen fibers, consequently improving the aesthetics of the scar, reducing the pain symptom and stimulating the local vascularization.

Studies<sup>5,6,8,10,11</sup> have been carried out to obtain more information about photo-bio modulator effects through the irradiation of LED light. However, there is a shortage of studies on the healing of burn in human tissues<sup>11</sup>. Although the literature presents information on the action mechanism of light emitting from diodes, which indicate positive stimulation in the cicatricle process, the application of LED as a therapeutic possibility in the burn should be studied and its effects clarified, so that the use of this resource optimizes the physiotherapeutic approach in the treatment of injuries in burn patients, ensuring improvement of skin healing and reducing the risks for the development of motor and functional sequelae.

Thus, the objective of the present study was to review the literature on the use of LED light and its effects on tissue healing of burn injuries.

## Materials and methods

The study consisted of a systematic review of the literature, conducted in August 2017 using the Bireme, PubMed and PeDro databases, with the English descriptors "burn", "LED", "LED light" ; "Physical therapy", combined with each other, two by two in the databases through the Boolean operator AND.

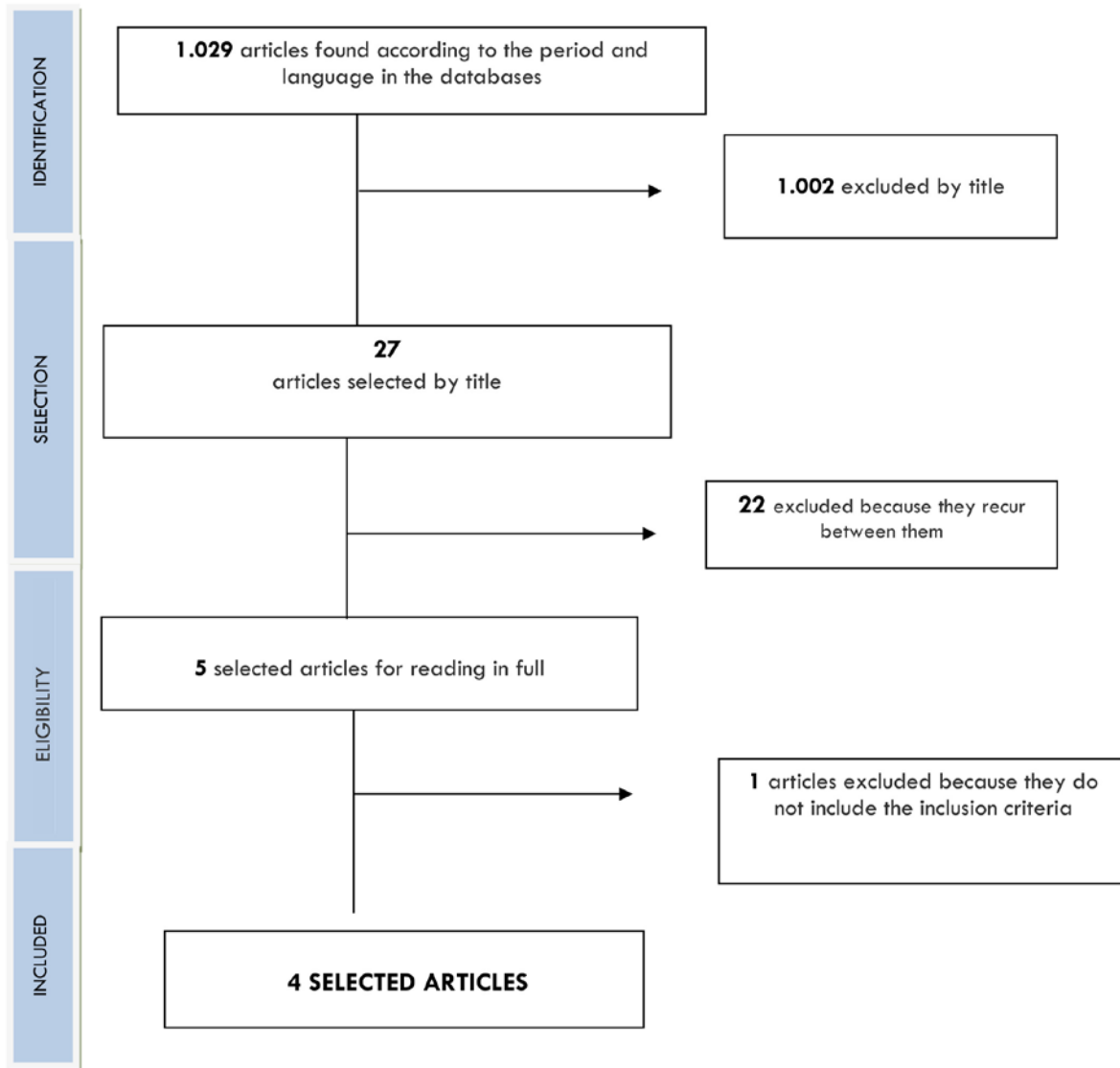
The study included articles that addressed the use of LED in the specific healing of burns, published in the last five years (2012 -2017), in the English and Portuguese languages. The exclusion criteria were articles that addressed the use of LED in tissue healing in general. The selection of articles was carried out by two authors, and there was no consensus between the two, a third author would be called, which was not necessary in this search.

This study followed the recommendation PRISMA (Preferred Reporting Items for Systematic Reviews and Meta-Analysis), used to assist in the construction of systematic reviews and meta-analyzes<sup>12</sup>. In order to maximize the evaluation and use of the information presented by the studies, was used Guideline ARRIVE (Animals in Research: Reporting In Vivo Experiment)<sup>13</sup>.

## Results

Through the initial search in the databases, 1,029 articles were found. Of these, only four articles considered the inclusion criteria after all stages of selection and refinement of search according to the flowchart of figure 1, based on the model PRISMA<sup>12</sup>.

**Figure 1.** Flowchart of the different phases of the systematic review conducted in August 2017 on the action of LED light in the burn healing (Adapted from PRISMA, 2009)<sup>12</sup>



Thus, two studies comparing the effects of LEDs associated with other therapeutic resources used for burn healing and performing a clinical and histological analysis of the lesions were used<sup>14,15</sup>. One study evaluated the clinical cicatrization through digital photography<sup>15</sup> and another one analyzed histologically the lesions by burns<sup>16</sup>.

The total number of animals used in all the articles was 195 animals, all rodents. Two studies<sup>14, 17</sup>

used to cause the injury iron bar heated by direct flame for 40 seconds and, applied in the animals for 20 seconds causing complete destruction of the epidermis and dermis, characterizing a third-degree burn. One publication<sup>16</sup> cites the use of the fractional ablative CO<sub>2</sub> laser and another<sup>14</sup> using a copper plate at 100° C for 10 seconds, the synthesis of the included works is in the Table 1.

**Table 1.** Characterization of the included studies of the systematic review conducted in August 2017 on the action of LED light on the healing of burns (to be continued)

TITLE / MAGAZINE / COUNTRY	AUTHOR / YEAR / LANGUAGE	OBJECTIVE / TYPE OF STUDY	METHODOLOGY	LED PARAMETERS	ASSESSED PARAMETERS	DESPITE OBSERVED	CONCLUSIONS	GUIDELINE ARRIVE
<ul style="list-style-type: none"> <li>Effects of red laser, infrared, photodynamic therapy, and green LED on the healing process of third-degree burns: clinical and histological study in rats;</li> <li>Lasers Med Sci</li> <li>Brazil</li> </ul>	<ul style="list-style-type: none"> <li>Carão et al.</li> <li>2015</li> <li>English</li> </ul>	<ul style="list-style-type: none"> <li>To evaluate the effects of red laser, infrared, photodynamic therapy and green LED in the healing process of burns in rats.</li> <li>Controlled Study</li> </ul>	<ul style="list-style-type: none"> <li>Injury caused in 100 animals, divided into 5 groups of 20 and subdivided into 5 animals to be examined on the 3rd, 7th, 14th and 21st days.</li> <li>G1: control;</li> <li>G2: red laser;</li> <li>G3: infrared;</li> <li>G4: photodynamic therapy (PDT);</li> <li>G5: Green LED.</li> <li>Applied daily except on the day of sacrifice.</li> </ul>	<ul style="list-style-type: none"> <li><math>\lambda</math>520 a 550 nm, 60 J/cm<sup>2</sup>, 60mW, 10</li> </ul>	<ul style="list-style-type: none"> <li>Clinical and histopathological analyses of cicatrice retraction, water consumption, inflammatory infiltrate collagen synthesis and morphology.</li> </ul>	<ul style="list-style-type: none"> <li>On the 14th day, all treatment groups presented scar retraction, but on the 21st day, the red laser group had a greater retraction. Collagen has improved in quality for all groups. However the infrared laser group had higher production compared to the control group, red laser and PDT, showing the same as the LED.</li> <li>While the red laser showed higher output than the control and LED.</li> </ul>	<ul style="list-style-type: none"> <li>Red and infrared laser, PDT, and LED demonstrated beneficial aspects in the acceleration of the cicatrice process in third degree burns in rats.</li> <li>There was production and maturation of collagen, analgesic effects, associated to the increase of water and food consumption compared to the control group and cicatrice retraction at 21 days in the animals treated with red and infrared laser in relation to the other groups.</li> </ul>	14/20

Source: ICS, 2017

**Table 1.** Characterization of the included studies of the systematic review conducted in August 2017 on the action of LED light on the healing of burns (continuation)

TITLE / MAGAZINE / COUNTRY	AUTHOR / YEAR / LANGUAGE	OBJECTIVE / TYPE OF STUDY	METHODOLOGY	LED PARAMETERS	ASSESSED PARAMETERS	DESPITE OBSERVED	CONCLUSIONS	GUIDELINE ARRIVE
<ul style="list-style-type: none"> <li>Green LED light has anti-inflammatory effects on burns in rats</li> <li>Burn</li> <li>Brazil</li> </ul>	<ul style="list-style-type: none"> <li>Catão et al.</li> <li>2016</li> <li>English</li> </ul>	<ul style="list-style-type: none"> <li>Evaluate by histological analysis the effects of green LED on inflammatory cells in burn lesions of rats.</li> <li>Controlled Study</li> </ul>	<p>Injury caused in 40 rats, divided into:</p> <ul style="list-style-type: none"> <li>G1 - control;</li> <li>G2-LED green.</li> </ul> <p>The animals subdivided into 5 subgroups for histological observation on the 3<sup>rd</sup>, 7<sup>th</sup>, 14<sup>th</sup> and 21<sup>st</sup> day. Applied daily except on the day of sacrifice.</p>	<p>λ 520, 550 nm, 60 J / cm<sup>2</sup>, 60 mW for 10 s, at four points of the lesion.</p>	<p>Histological analysis on the alteration of the number of inflammatory cells.</p>	<p>On the 3<sup>rd</sup> day there was no significant difference in inflammatory cells. From the 7<sup>th</sup> there was a reduction in the number of inflammatory cells, compared to the control group.</p>	<p>The study suggests that the green light has anti-inflammatory action and favors burn healing in rats.</p>	11 / 20
<ul style="list-style-type: none"> <li>The systemic effect of 830-nm LED phototherapy on the wound healing of burn injuries: A controlled study in mouse and rat models</li> <li>Journal of Cosmetic and Laser Therapy</li> <li>Republic of Korea</li> </ul>	<ul style="list-style-type: none"> <li>Lee e Kim</li> <li>2012</li> <li>English</li> </ul>	<ul style="list-style-type: none"> <li>To evaluate the systemic effects in the application of LED 830nm in burns in rats</li> <li>Controlled study</li> </ul>	<p>Injury caused in 5 animals, divided into 2 groups:</p> <ul style="list-style-type: none"> <li>G1: LED (n = 3);</li> <li>G2: control (n = 2)</li> </ul> <p>Applied after the burn, in the 1<sup>st</sup>, 5<sup>th</sup> and 6<sup>th</sup> days.</p>	<p>λ 830 nm, 66 J cm<sup>-2</sup>, 55 mW, 20 min.</p>	<p>Clinical cicatrization evaluation in rats, by means of digital photography, performed on days 1, 5, 6 and 7.</p>	<p>From the 5<sup>th</sup> day the treatment group presented more advanced healing in relation to the control group. On the 7<sup>th</sup> day G1 presented incomplete scarring at 5 burn sites and completed at 3 sites. While the control group presented</p>	<p>The use of LEDs at 830nm in animal burns induced improvement in wound healing, suggesting a systemic influence in the application of low level light therapy through LED.</p>	7 / 20

Source: ICS, 2017

**Table 1.** Characterization of the included studies of the systematic review conducted in August 2017 on the action of LED light on the healing of burns (conclusion)

TITLE / MAGAZINE / COUNTRY	AUTHOR / YEAR / LANGUAGE	OBJECTIVE / TYPE OF STUDY	METHODOLOGY	LED PARAMETERS	ASSESSED PARAMETERS	DESPITE OBSERVED	CONCLUSIONS	GUIDELINE ARRIVE
<ul style="list-style-type: none"> <li>• Effect of Low-Power Laser (LPL) and Light-Emitting Diode (LED) on Inflammatory Response in Burn Wound Healing/</li> <li>• Inflammation</li> <li>• Brazil</li> </ul>	<ul style="list-style-type: none"> <li>• Silveira et al</li> <li>• 2016</li> <li>• English</li> </ul>	<ul style="list-style-type: none"> <li>• Investigate the molecular and biochemical changes in the epidermal healing of burns after therapeutic treatment with LPL (low power laser) and LED</li> <li>• Experimental study</li> </ul>	<ul style="list-style-type: none"> <li>• 50 rats, divided and 6 groups:</li> <li>• G1: skin without injury (Sham);</li> <li>• G2: burn wounds (BWs);</li> <li>• G3: LPL 660 nm;</li> <li>• G4: LPL 904 nm;</li> <li>• G5: LED 632 nm;</li> <li>• G6: LED 850 nm</li> </ul> <p>Application were during seven sessions once a day, 24 h after induction of the injury.</p>	<p>Red LED:</p> <ul style="list-style-type: none"> <li>• λ 632 nm, 14 mW cm<sup>2</sup>, for 10 min</li> </ul> <p>Infrared LED: λ</p> <ul style="list-style-type: none"> <li>• 850 nm, 33 mW / cm<sup>2</sup>, for 10 min</li> </ul>	<p>Histological analysis of oxidative stress and inflammatory mediators in tissue healing.</p> <p>Clinical evaluation of wound border size was calculated in cm<sup>2</sup> by software.</p>	<p>There were decreases in wound closure at the 660 nm laser and in the 850 nm LEDs compared to the injury group. There was better organization of the tissue in both groups of LEDs.</p>	<p>Treatments with LPL at 660 nm and the 850 nm LED provided protection against oxidative stress.</p> <p>The LPL 660 nm and LED 850 nm appeared to reduce the inflammatory response and oxidative stress, diminishing dermal necrosis and increasing the formation of granulation tissue, accelerating the burn wounds repair.</p>	13/20

incomplete at all sites.

Source: ICS, 2017

## Discussion

All the studies included in this review were experimental studies<sup>14-17</sup> and suggest that the application of LED in the healing of burns contributed to the process of tissue repair with anti-inflammatory photo bio modulator action in animals.

Catão et al.<sup>17</sup> used the green LED to treat burn in rats and noticed a reduction in the number of inflammatory cells after the 7th day of application. In a similar study, Meyer et al.<sup>18</sup> evaluated the effects of green and red LEDs on the healing of cutaneous wounds in rats after lesion caused by a surgical incision of 2cm<sup>2</sup> on the backs of animals. The authors observed that the group treated with green LED presented a moderate number of inflammatory cells in the acute inflammation, but in the chronic inflammation there were more inflammatory cells in the granulation tissue when compared to the control group and moderate collagen deposition. The red LED treatment group showed more developed granulation tissue, higher amount of collagen and fewer inflammatory cells compared to the group treated with green LED. The study by Meyer et al<sup>18</sup> concludes that the application of the green LED favored anti-inflammatory effects, however, the red LED was more effective than the green LED, type of LED light used by Catão et al.<sup>17</sup>.

In particular, Catão et al.<sup>17</sup> evaluated burn injuries, while Meyer et al.<sup>18</sup> evaluated surgical wounds. However, the tissue healing process follows the same phases for both types of lesion. Another difference between the studies is the time of application of the LED effect, where the first LED applied immediately after the burn and followed until the 21st day, while Meyer et al<sup>18</sup> applied the LED 24 hours after the injury and evaluated until the 7th day of healing. However, in both studies there was a reduction in the number of inflammatory cells after application of the green LED.

The literature describes the anti-inflammatory action of LED as a positive effect in relation to the cicatricle process<sup>17-19</sup>. Where satisfactory results are obtained in scars by second intention<sup>17</sup> as in the case of burn injuries<sup>1</sup>. However, in a comparative study, Souza et al.<sup>20</sup> used the green (530 nm), blue (460 nm) and red (700 nm) and red and infrared low power laser

(LLLT), to compare the effects of these features on the angiogenesis of cutaneous wounds in rodents. The authors reported that the groups treated with green and red LEDs showed a significant increase in angiogenesis compared to the red laser. However, there was no difference between the blue LED group and the control group. Although this is an important aspect in scar repair, none of the authors included in this review evaluated angiogenesis after using LED on burns.

Of the analyzed articles, the work elaborated by Lee and Kim<sup>16</sup>, carried out evaluation only from the clinical point of view. The authors noticed that the animals treated with the LED 830 nm showed more advanced healing when the lesions by burn were evaluated clinically through digital photography, suggesting a systemic influence on the LED application. The authors did not perform histological or biochemical analysis that could substantiate the clinical results.

Similarly to Lee and Kim<sup>16</sup>, but performed in human, Ferreira, Fronza and Prado<sup>6</sup>, in a study to evaluate the efficacy of the use of laser associated with LED in the treatment of sequelae in the hands of a burn victim patient, used the red LED (632 nm) and the infrared LED (850 nm) associated with the high power laser and perceived improvement in skin appearance and hydration in the treated region. The authors also used digital photography to evaluate the effects of treatment and a scale that analyzed color, texture, hydration, tissue irregularities, volume and distensibility of the skin. The laser and LED application protocol used by the authors was composed of eight sessions, 2 times a week, performing only one initial session of fractured erbium laser, for 5 minutes, to remove tissue scarring I, followed by photo modulation of the red and infrared LEDs for 15 minutes, with a 48-hour interval between applications. Although different from the work of Lee and Kim<sup>16</sup> regarding the parameters of the LED and the fact of the latter they apply the infrared LED in only three sessions during a total treatment of six days, both authors found favorable results for this therapy.

The clinical evaluation of healing addresses subjective aspects of the evaluator. The use of standardized and scientifically validated instruments

with objective observation favors the reproducibility of the research and verification of the results of the visual observation of the researchers<sup>21</sup>. The International Scale of Healing in Vancouver is used for clinical evaluation of scars and is suggested in the literature as a valid and reliable instrument for scar evaluation also in burn patients<sup>3</sup>.

A useful and low-cost tool, developed to evaluate the functional and aesthetic aspects of the scar, composed of four items to be evaluated pigmentation, vascularity, flexibility and height. The final score varies from 0 to 13, being the lowest score corresponding to a better result of regeneration and tissue healing. The use of a specific instrument to evaluate the healing process helps to plan the treatment and minimizes complications due to burns<sup>22</sup> favoring a standardization of the cicatricle evaluation, increasing the reliability of this evaluation and allowing the comparison of the results and reproducibility of the research<sup>21</sup>.

The LED besides favoring the tissue repair, seems to avoid or minimize the development of hypertrophic or keloid scars. Barolete and Boucher<sup>22</sup>, in a case study, used the infrared LED (805 nm) for the cicatricle treatment of three patients with hypertrophic and keloid scars. The LED was applied daily for 15 minutes by the patients at their home for 30 days. There was improvement in the appearance, height, and scar gravity of the scar through the Vancouver International Scale of Healing.

Silveira et al.<sup>15</sup> carried out an experimental study to investigate the alterations of inflammatory mediators and oxidative stress in burn healing after treatment with low power laser and the LED, reporting improvement in tissue healing in the groups treated with LEDs 632 and 850 nm and in the laser group 660 nm, with improvement of the tissue organization in the treatment with LED 632 nm, with the groups treated with LEDs 850 nm and laser 660 nm promoted a significant reduction in oxidative stress. The authors conclude that laser and LED applications can reduce the inflammatory response in the burn, by activating IL-6, blocking the effects of reactive oxygen species and allowing stimulation for the tissue repair process.

The exposure of cells to LPL increases cellular activities and generates therapeutic effects, favoring the acceleration of the cicatricial process, besides analgesia, after the use of red and infrared light<sup>24</sup>. The biostimulatory effects of laser and LED phototherapy depend on the parameters used, due to the specific characteristics of the intracellular photoreceptors, which are responsible for the absorption of light, generating varying effects on each irradiated tissue<sup>19</sup>.

Corroborating the results of Silveira et al.<sup>15</sup>, where laser and LED favored tissue healing, inducing reduction of oxidative damage, Barolete<sup>19</sup>, Freitas and Hamblin<sup>25</sup>, describe that the mechanisms involved in the difficulty of wound healing seem to be related to the increase of oxidative stress, as this impairs tissue repair. In addition, irradiation with LPL points for other anti-inflammatory effects with stimulation in the proliferation of fibroblasts, also favoring cicatrization<sup>25</sup>.

In this way, photo bio modulation acts by inducing intracellular photochemical reactions, which modify the oxidative stress of the cell favoring the positive response during the process of injury repair<sup>25</sup>, besides stimulating the production of growth factors in damaged cells<sup>26</sup>.

Catão et al.<sup>14</sup> carried out a comparative study between red, infrared, LED and photodynamic therapy (PDT) in the healing process of burns, and evaluated cicatricle retraction, water and food consumption, inflammatory infiltrate, synthesis and organization of collagen in the period of 21 days of treatment, performing clinical and histomorphological analysis in the 3rd, 7th, 14th and 21st days. the researchers found that up to the 14th day all treated groups had a higher rate of wound retraction when compared to the control group. However, on the 21st day, the group treated with infrared showed a greater cicatricle retraction. The authors stated that the groups treated with red and infrared laser presented better results in scar retraction compared to the other groups, including better results than those obtained using LED.

With respect to inflammatory infiltrate and collagen production, on the 14th day there was



presence of neutrophils, lymphocytes and superficial macrophages, with granulation tissue composed of thick collagen and newly formed vessels, with indication of reepithelialization. There was higher collagen production in the group treated with infrared, in which on the 14th day there was predominance of type I fiber in 60% of the animals in the intervention groups and in the control group in 20% of the animals.

Regardless of the morphological and organizational aspects, there was no variation in the description of these fibers which were corrugated, thin, shortened and in a reticular pattern. These observed aspects improved in the analysis of the 21st day for the group of infrared laser and LED. However, from the statistical point of view, the area of collagenization from LED induction, obtained a significant difference at 21 days in relation to the control group, and no difference was observed with the other treatments. It is important to note that the authors describe the benefits of LED application in the healing process of burns, although they have found better results associated with red and infrared laser.

In this study, Catão et al.<sup>14</sup> concluded that infrared and red laser presented better results in cicatricial retraction, however, regarding the inflammatory infiltrate, the authors did not compare the treated groups, only reported the presence of the cells found on the days of analysis. However, through the presented results it is possible to notice that there was an adequate presence of inflammatory cells.

Phototherapy or photobiomodulation is used by radiation to alter biological activity<sup>23</sup>, through the LPL used by LLLT laser therapy and light-emitting diodes, LEDs, used to stimulate tissue healing<sup>9,18,24,25,27</sup>, as well as for anti-inflammatory and analgesic therapeutic effects<sup>27</sup>.

The authors did not report information on analgesia and pain. This may be justified by the fact that the studies deal with animal evaluations. However, a case report on the use of LED for the treatment of venous ulcer in the elderly, with application of 2 times a week for 20 minutes, brought improvement of cicatrization and analgesia<sup>28</sup>. Although a study may be considered limited in the evaluation of this symptom, however, it may be suggested that similar

results are obtained through LED therapy in terms of analgesia.

The literature describes that the LPL can use wavelengths between 600 and 1100 nm, applied through LLLT and LED<sup>25</sup>. No entanto, existem autores que apresentam possibilidades de comprimento de onda a partir de 390 – 600nm, used for superficial tissues, and between 600-1100nm for deep tissues<sup>25</sup>. However, there is a consensus in the literature regarding the wavelength between 700-780nm has limited biochemical activity, and is therefore not frequently indicated<sup>19,24,25</sup>. The possibilities for using the LED include the light blue (400-470nm), green (470-550 nm), red (630nm-700nm) and infrared (700-1200nm). In which, the longer the wavelength, the deeper the penetration of light into the tissue<sup>19</sup>. In the articles analyzed in this work, the wavelengths ranged from 520 nm to 850 nm, corresponding to the light spectrum of the green and infrared LEDs. The green LED was suggested for anti-inflammatory effects on burn<sup>16</sup> and the infrared LED acting on the cicatricial improvement of the lesions<sup>14-16</sup>.

The LED converts electrical energy into light, emitting a narrow and non-coherent spectrum with wavelengths that range from visible light to infrared<sup>19</sup>. The emitted energy is absorbed by chromophores or photoreceptors, intracellular components that absorb light and are responsible for the photochemical effects that generate therapeutic responses<sup>19,27</sup>. The chromophores or photoreceptors are located within the mitochondria and plasma membranes, stimulating intracellular processes<sup>24</sup>. The absorption of energy generates an increase in the enzymatic activity, which mediates the transport of electrons, generates a cascade of events, which alter intracellular signaling and alter transcription factors related to cell proliferation, tissue repair and regeneration<sup>24,25</sup>.

In a review of the literature on the effects of laser and LED on wound healing, Chaves et al.<sup>29</sup>, reports that both resources promote similar therapeutic effects, acting in the reduction of inflammatory cells, increased fibroblast proliferation and collagen synthesis, stimulating angiogenesis and formation of granulation tissue. Confirming what other comparative studies have highlighted about these resources, where both have similar results in the healing of cutaneous wounds<sup>20,28,31</sup>.

However, the costs generated by the difficulty of healing in some individuals require the search for low-cost alternatives<sup>31,32</sup> and LED has been described as an alternative for laser therapy<sup>5,31,33</sup>. In the case of LED use, there is no concern about the risk of eye damage such as blindness, related to its applicability<sup>24</sup>, being considered an easy and safe handling equipment<sup>31</sup>, which can make it feasible to apply it to the less favored population<sup>28</sup> and even be used at home by the patient himself without the need for supervision<sup>23</sup>. There are no reports in the literature of negative effects on the use of light emitting diodes, as well as no contraindications to the LED. However, there should be caution in the application of this resource in epileptic patients or with photophobia<sup>19</sup>.

It is known that there is an ideal specific dose for the clinical application of light<sup>24</sup>, because the effects on biological tissues depend on the wavelength, amount and time of application, considering the interval of application and number of sessions<sup>18</sup>. It is important to know the therapy to better indicate it.

The use of diversified parameters related to the wavelength, irradiation time and power of the LED, described for the treatment of burn injuries in animals by the studies analyzed in this review, made it difficult to compare them and indicate an ideal protocol. In addition, the literature presents few studies aimed at the application of LED in the cicatricle process of burns in humans, making it difficult to establish a protocol for the use of LED in the healing of burns.

Considering also that the tissue repair of the human skin presents more complex mechanisms of regeneration compared to experimental animals, requires that in vivo studies should be performed to allow the standardization of specific therapeutic parameters for clinical use of LED in healing<sup>5,26</sup>. Based on the above, it can be considered that LED therapy in the treatment of skin burns seems to be well indicated. Few studies have brought the evaluation of this therapeutic resource in the context of tissue healing of burns, but the articles included in this review presented satisfactory results for LED use.

Regardless of this, all the studies presented limitations in their methodologies, concerning the number of the sample, type of clinical and / or histological

evaluation performed. Thus, the production of greater scientific knowledge about the use of LED, in particular in the repair of burn wounds, should be encouraged, aiming at the use of this resource in a broader way and allowing the establishment of protocols useful for this population.

## Conclusion

From the articles analyzed in this review it was observed that the LED light is beneficial for cicatricle burn repair in animal and improves the histological aspects in the treated tissues. However, the number of articles related to the applicability of these resources for scar treatment in burn injuries is still limited other studies should be conducted aiming at stronger scientific evidence for the establishment of adequate protocols and evidence of the effectiveness of this therapy to assist in the rehabilitation of burn patients.

## Author contributions

Araújo MJS participated in the study conception and design, search and interpretation of the data and writing of the manuscript. Martins GB participated in the study conception and design, search and interpretation of the data, writing of the manuscript and supervision of the research.

## Competing interests

No financial, legal or political competing interests with third parties (government, commercial, private foundation, etc.) were disclosed for any aspect of the submitted work (including but not limited to grants, data monitoring board, study design, manuscript preparation, statistical analysis, etc.).

## References

1. Andrade AG, Lima CF, Albuquerque AKB. Efeitos do laser terapêutico no processo de cicatrização das queimaduras: uma revisão bibliográfica. *Rev Bras Queimaduras*. 2010;9(1):21-30.
2. Bravo BSF, Bastos JT, Balassiano LKA, Rocha CRM, Bravo LG. Tratamento de cicatriz de queimadura com luz intensa pulsada e laser ablativo fracionado erbium. *Rev Bras Queimaduras*. 2016;15(4):274-277.
3. Abalí MOT, Bravo BSF, Zylbersztejn D. Luz Intensa Pulsada no tratamento de cicatrizes após queimaduras. *Surg Cosmet Dermatol*. 2014;6(1):26-31.

4. Rodrigues Júnior JL, Bastos NNA, Coelho PAS. Terapia ocupacional em queimados: pesquisa bibliográfica acerca da reabilitação física junto a indivíduos com queimaduras. *Rev Bras Queimaduras*. 2014;13(1):11-17.
5. De Paula S. Comparação do laser e do led no processo de cicatrização em feridas cutâneas: uma revisão. *Revista Ciência e Saúde*. 2016;9(1):55-61. doi: [10.15448/1983-652X.2016.1.21840](https://doi.org/10.15448/1983-652X.2016.1.21840)
6. Ferreira FS, Fronza VL, Prado ALC. Laser érbium fracionado e fotobiomodulação por diodos emissores de luz em sequelas de queimaduras nas mãos: estudo piloto - caso boate Kiss. *Fisioterapia Brasil*. 2015;16(3):S31-S35.
7. Tizatto VF, Carrer T, Schuster RC. Efeitos da Terapia por Indução de Colágeno na qualidade de cicatrizes de queimaduras – Relato de caso. *Rev Bras Queimaduras*. 2015;14(1): 49-53.
8. Moura RO, Nunes LCC, Carvalho MEIM, Miranda BR. Efeitos da luz emitida por diodos (LED) e dos compostos de quitosana na cicatrização de feridas: Revisão Sistemática. *Rev Ciênc Farm Básica Apl*. 2014;35(4):513-518.
9. Siqueira CPCM, Toginho Filho DO, Lima FM, Silva FP, Durante H, Dias IFL, Duarte JL, Kashimoto RK, Castro VAB. Efeitos biológicos da luz: aplicação de terapia de baixa potência empregando LEDs (Light Emitting Diode) na cicatrização da úlcera venosa: relato de caso. *Semina: Ciências Biológicas e da Saúde*. 2009;30(1):37-46. doi: [10.5433/1679-0367.2009v30n1p37](https://doi.org/10.5433/1679-0367.2009v30n1p37)
10. Fortuny E, Soares AM, Freire A, Cabral PC, Froes P, Freire MG et al. Evolucion de los efectos del LED em el tejido dérmico de ratones. *Rev Chil Dermatol*. 2014;30(2):151-157.
11. Dias IFL, Siqueira CPCM, Toginho Filho DO, Duarte JL. Efeitos da luz em sistemas biológicos. *Semina: Ciências Exatas e Tecnológicas*. 2009;30(1):33-40.
12. Moher D, Liberati A, Tetzlaff J, Altman DG. Preferred Reporting Items for Systematic Reviews and Meta-Analyses: the PRISMA statement. *Plos Med*. 2009;6(7): e1000097. doi: [10.1371/journal.pmed.1000097](https://doi.org/10.1371/journal.pmed.1000097)
13. Kilkenny C, Browne WJ, Cuthill IC, Emerson M, Altman DC. Improving Bioscience Research Reporting: The ARRIVE Guidelines for Reporting Animal Research. *PLoS Biol*. 2010; 8(6):e1000412. doi: [10.1371/journal.pbio.1000412](https://doi.org/10.1371/journal.pbio.1000412)
14. Catão MHCV, Nonaka CFW, Albuquerque Junior RLC, Bento PM, Costa RO. Effects of red laser, infrared, photodynamic therapy, and green LED on the healing process of third-degree burns: clinical and histological study in rats. *Lasers Med Sci*. 2015;30(1):421-428. doi: [10.1007/s10103-014-1687-0](https://doi.org/10.1007/s10103-014-1687-0)
15. Silveira PCL, Ferreira KB, Rocha FR, Pieri BLS, Pedroso GS, Souza CT et al. Effect of Low-Power Laser (LPL) and Light-Emitting Diode (LED) on Inflammatory Response in Burn Wound Healing. *Inflammation*. 2016;39(4):1396-1404. doi: [10.1007/s10753-016-0371-x](https://doi.org/10.1007/s10753-016-0371-x)
16. Lee GY, Kim WS. The systemic effect of 830-nm LED phototherapy on the wound healing of burn injuries: A controlled study in mouse and rat models. *J Cosmet Laser Ther*. 2012;14(2):107-110. doi: [10.3109/14764172.2011.649762](https://doi.org/10.3109/14764172.2011.649762)
17. Catão MCV, Costa RO, Nonaka CFW, Junior RLC, Costa IRRS. Green LED light has anti-inflammatory effects on burns in rats. *Burns*. 2016;42(2):392-396. doi: [10.1016/j.burns.2015.07.003](https://doi.org/10.1016/j.burns.2015.07.003)
18. Meyer PF, Araujo HG, Carvalho MGF, Tatum BIS, Fernandes ICAG, Ronzio AO et al. Avaliação dos efeitos do LED na cicatrização de feridas cutâneas em ratos Wistar. *Fisioter Bras*. 2010;11(6):428-432
19. Barole D. Light-Emitting Diodes (LEDs) in Dermatology. *Semin Cutan Med Surg*. 2008; 27(4):227-238. doi: [10.1016/j.sder.2008.08.003](https://doi.org/10.1016/j.sder.2008.08.003)
20. Sousa APC, Paraguassú GM, Silveira NTT, Souza J, Cangussú MCT, Santos JN et al. Laser and LED phototherapies on angiogenesis. *Lasers Med Sci*. 2013;28(3):981-987. doi: [10.1007/s10103-012-1187-z](https://doi.org/10.1007/s10103-012-1187-z)
21. Marques CMG, Dutra LR, Tibola J. Avaliação fisioterapêutica da cicatrização de lesões por queimaduras: revisão bibliográfica. *Rev Bras Queimaduras*. 2015;14(2):140-144.
22. Santos MC, Tibola J, Marques CMG. Tradução, revalidação e confiabilidade da Escala de Cicatrização de Vancouver para língua portuguesa – Brasil. *Rev Bras Queimaduras*, 2014;13(1):26-30.
23. Barolet D, Boucher A. Prophylactic Low-Level Light Therapy for the Treatment of Hypertrophic Scars and Keloids: A Case Series. *Lasers in Surgery and Medicine*. 2010;42(6):597-601. doi: [10.1002/lsm.20952](https://doi.org/10.1002/lsm.20952)
24. Avci P, Gupta A, Sadasivam M, Vecchio D, Pam Z, Pam N et al. Low-level laser (light) therapy (LLLT) in skin: stimulating, healing, restoring. *Semin Cutan Med Surg*. 2013;32(1):41-52.
25. Freitas LF, Hamblim MR. Proposed Mechanisms of Photobiomodulation or Low-Level Light Therapy. *IEEE J Sel Top Quantum Electron*. 2016;22(3):1-37. doi: [10.1109/JSTQE.2016.2561201](https://doi.org/10.1109/JSTQE.2016.2561201)
26. Jere SW, Abrahamse H, Houeild NN. The JAK/STAT signaling pathway and photobiomodulation in chronic wound healing. *Cytokine Growth Factor Rev*. 2017;38:73-79. doi: [10.1016/j.cytogfr.2017.10.001](https://doi.org/10.1016/j.cytogfr.2017.10.001)

27. Anders JJ, Lanzafame RJ, Arany PR. Low-level light/laser therapy versus photobiomodulation therapy. *Photomed Laser Surg.* 2015;33(4):183-184. doi: [10.1089/pho.2015.9848](https://doi.org/10.1089/pho.2015.9848)
28. Porto NPC, Garcia VVCG, Munguba EJLA, Araujo RR, Alves LS. Benefícios do LED em úlcera varicosa de idoso diabético. In: 4º Congresso Internacional de Envelhecimento Humano, 2015, Campina Grande-PB. Anais CIEH. Campina Grande-PB: Realize Eventos e Editora, 2015. v. 2.
29. Chaves MEA, Araujo AR, Piancastelli ACC, Pinotti M. Effects of low-power light therapy on wound healing: LASER x LED. *An Bras Dermatol.* 2014;89(4):616-623. doi: [10.1590/abd1806-4841.20142519](https://doi.org/10.1590/abd1806-4841.20142519)
30. Souza APC, Santos JN, Reis Junior JA, Ramos TA, Souza J, Canguassú MCT et al. Effect of LED Phototherapy of Three Distinct Wavelengths on Fibroblasts on Wound Healing: A Histological Study in a Rodent Model. *Photomedicine Laser Surgery.* 2010;28(4):547-552. doi: [10.1089/pho.2009.2605](https://doi.org/10.1089/pho.2009.2605)
31. Dall Agnol MA, Nicolau RA, Lima CJ, Munin E. Comparative analysis of coherent light action (laser) versus non-coherent light (light-emitting diode) for tissue repair in diabetic rats. *Lasers Med Sci.* 2009;24(6):909-916. doi: [10.1007/s10103-009-0648-5](https://doi.org/10.1007/s10103-009-0648-5)
32. Guedes JS, Caldas RS, Leal MRD. Efeitos do LED e Laser em Úlceras Venosas: Revisão Narrativa da Literatura. *Interbio.* 2016;10(1):34-40.
33. Vinck EM, Cagnie BJ, Cornelissen MJ, Declercq HA, Cambier DC. Increased fibroblast proliferation induced by light emitting diode and low power laser irradiation. *Lasers Med Sci.* 2003;18(2):95-99. doi: [10.1007/s10103-003-0262-x](https://doi.org/10.1007/s10103-003-0262-x)