

IMMUNOPATHOGENESIS OF ORAL MUCOSITIS INDUCED BY CHEMOTHERAPY AND / OR RADIOTHERAPY: STATE OF ART

Juliana Borges de Lima Dantas¹, Gabriela Botelho Martins², Hayana Ramos Lima³, Manoela Pereira Carrera⁴, Sílvia Regina de Almeida Reis⁵, Alena Peixoto Medrado⁶

Corresponding author: Alena Peixoto Medrado - apmedrado@bahiana.edu.br

¹MSc in Dentistry candidate at BAHIANA - School of Medicine and Public Health. Salvador, Bahia, Brazil.

²PhD in Odontology. Professor at the Health Sciences Institute of the Federal University of Bahia. Salvador, Bahia, Brazil.

³PhD in Applied Dental Sciences. Professor at the Metropolitan Union of Education and Culture. Lauro de Freitas, Bahia, Brazil.

⁴PhD in Stomato-pathology. Professor at the State University of Bahia. Salvador, Bahia, Brazil.

⁵PhD in Oral Pathology. Professor at Bahiana - School of Medicine and Public Health. Salvador, Bahia, Brazil.

⁶PhD in Human Pathology. Professor at BAHIANA - School of Medicine and Public Health. Salvador, Bahia, Brazil.

ABSTRACT | Introduction: Oral mucositis is a common and worrying clinical condition in patients undergoing radiotherapy of the head and neck regions and aggressive chemotherapy. Mucositis manifests as a continuous process, which begins with erythematous and atrophic lesions that can progress to very painful ulcers. The immunopathogenesis of oral mucositis is considered a complex cascade of biological events, and advances on its understanding might result in promising and effective therapies. **Objectives:** The aim of this study is to highlight the recent findings of the immunopathogenesis of oral mucositis induced by chemotherapy and / or radiotherapy and their possible therapeutic agents. **Material and methods:** Scientific articles were selected in Pubmed and LILACS basis from December 2015 to May 2016, using the key words in English “mucositis etiopathogenesis” and “mucositis”. Were found in Pubmed 107 articles and LILACS 61. The articles were selected after reading and were chosen those which reported detail on the immunopathology of oral mucositis, and an update on the biological causes of this clinical condition. **Results and conclusion:** The literature indicates that histopathological changes related to oral mucositis, including apoptotic phenomenon, the action of certain chemical mediators and the influence of the oral cavity microbiota promote a better understanding of the immunopathogenesis of this type of injury and their biological development. Therefore, additional clinical studies based on scientific evidence are needed to get a better understanding of the immunopathology of oral mucositis and the determination of preventive agents and effective therapeutic for this deleterious effect arising from antineoplastic treatment.

Key-words: Mucositis; Radiotherapy; Chemotherapy.

INTRODUCTION

Mucositis is one of the most debilitating, symptomatic and worrying side effect of cancer treatment and can affect any portion of the gastrointestinal tract (GIT) from mouth to anus¹. This is a common clinical condition in patients undergoing head and neck radiotherapy, aggressive chemotherapy treatments, or interventions that combine radio and chemotherapy².

Clinically, oral mucositis manifests itself as a continuous process. Initially, erythematous, atrophic lesions appear and may progress to bleeding ulcers, penetrating fully into the submucosa. Narcotic analgesia and even hospitalization are routinely necessary due to the intensity of the pain and dysphagia related to the mucositis. Furthermore, this condition adversely affects quality and increases the cost of treatment, whereas reducing patients' tolerance to treatment^{2,3}. Depending on the degree of aggressiveness, mucositis threatens the efficacy of treatment by necessitating breaks in radiation therapy, chemotherapy dose reductions, and modifications in the selection of antineoplastic agents³.

Historically, the pathogenesis of oral mucositis was based on the assumption that this clinical condition arose solely as a consequence of epithelial injury⁴. It was believed that the direct damage resulting from cytotoxic treatment in the basal layer of led to impaired epithelial self-renewing and, consequently, to atrophy and ulceration^{3,5}. Furthermore, it was hypothesized that the process was facilitated by trauma and oral microorganisms³. However, this simple linear model of damage, ulceration and healing can no longer be considered appropriate, and new evidences reveal a more complex series of biological events leading to oral mucositis⁵.

The recognition that mucositis develops, not only through direct cell injury mediated by chemotherapy or radiation, but more significantly as a consequence of a complex cascade of biological events, has provided numerous targets for intervention that are now being exploited⁶. Although there is no "gold standard" therapy to prevent or treat oral mucositis at the present, the development of an effective intervention is seen as a high priority in oncological

supportive care. Advances in the understanding of the immunopathogenesis of this undesired and detrimental condition resulted in the identification of a range of promising targets for effective treatment and prevention of its occurrence^{3,7}.

The aim of this narrative literature review is to highlight recent discoveries related to the immunopathogenesis of oral mucositis as well as to document the possible effects of this clinical condition in the proposed antineoplastic treatment of patients.

MATERIALS AND METHODS

The methodological strategy defined for this study was a narrative literature review based on research articles carried in the database Pubmed and LILACS from December 2015 to May 2016, using the intersection of the following descriptors in English "mucositis etiopathogenesis and "oral mucositis ".

The article selection was based on the titles that addressed the immunopathogenesis of oral mucositis and the general aspects of the treatment, its clinical applicability, clinical outcomes, and cellular changes resulting from this.

First, the available summaries were collected. A total of 107 articles were found in Pubmed and 61 in LILACS. After reading the selected articles the chosen articles were those that provided evidence of the immunopathology of oral mucositis and provided an update on the immunopathogenesis of mucositis according to the following inclusion criteria: articles relevant to the topic and that had been published between from 1992 to 2015. Articles that did not have abstracts in the database were excluded from the study. Only articles written in English and Spanish were selected.

After prior examination, 43 articles were included in this narrative literature review.

LITERATURE REVIEW

Histopathological affections related to oral mucositis

Tissue integrity

The oral cavity is the beginning of the GIT tract. It is lined by stratified squamous epithelium which may or may not be keratinized. The epithelium of the lining mucosa is not keratinized, and is composed of the jugal mucosa, the labial mucosa, ventral surface of the tongue, floor of mouth and soft palate. In contrast, the masticatory mucosa, represented by the tongue dorsum, hard palate and gingiva have a keratinized epithelium. Although all the tissues of the mouth are susceptible to radiation-induced mucositis, only the lining mucosa develops chemotherapy-induced injury³.

The extracellular matrix (ECM) plays an important role in signalling between tissues and is a complex structural network of fibrous proteins, proteoglycans and glycoproteins. It is vital for maintenance of normal tissue morphology and wound healing⁸.

Epithelial tissue and ECM play a significant role in maintaining the integrity and function of the epithelial layer [2,9]. Intercellular occluding junctions act as a selectively permeable barrier to fluid flow between cells. A variety of physiological and pharmacological stimuli can modulate the barrier properties⁹. A number of studies have demonstrated drastic changes in tight junction permeability resulting from the action of certain cytokines, such as tumor necrosis factor (TNF- α), IL-1 and IL-6^{7,10-12}.

Action of cytotoxic agents on cell kinetics

Cytotoxic agents induce cell death in both tumour and healthy tissues via apoptosis¹³. Cells from oral mucosa and GIT are more susceptible to cell death due to increased proliferation rates¹⁴. Previous studies investigating the effect of epidermal growth factor (EGF) in a standard protocol of mucositis induced by administration of 5-fluorouracil in animal models, have shown that EGF stimulated epithelial cell proliferation and increased significantly the severity of mucositis indicating the importance of renewal

rate of the epithelium in determining susceptibility of the mucosa to chemotherapy induced injury¹⁵. It is well established that in oral mucositis lesions, there is apoptosis in the basal layer of the oral mucosa¹⁶.

Apoptotic changes not only occur within the oral epithelium, but also in the connective tissue, affecting mainly fibroblasts and endothelial cells. This process may be modified by both the ceramide pathway and genetic factors. Ceramide is a lipid present in abundance in the cell membranes and originated through the sphingomyelin pathway. Thus, ceramide may be involved in radiation-induced endothelial apoptosis, becoming a potential trigger of mucositis⁵. Similarly, pharmacologic inhibition of sphingomyelinase and ceramide synthase was found to reduce the intensity of experimental radiation-induced oral mucositis¹⁷.

Chemical mediators that enhance oral mucositis

The kinetics of mucositis suggests that the injury results from a series of biological events in which cellular mediators play an important role¹⁸. Increases in pro-inflammatory cytokine profile is also associated with the development of mucositis and likely play important roles in signaling pathways leading to tissue injury³. Cytokines are prevalent within the affected tissue and are also detected in peripheral blood⁵. Studies have shown a significant increase in the levels of pro-inflammatory cytokines during chemotherapy and / or radiotherapy of head and neck, such as TNF- α ^{19,20} and IL-6^{12,19,21}.

COX-1 and COX-2 mediate the conversion of arachidonic acid into PGE2 and PGI2, promoting pain through direct action on the prostaglandin receptors at neurons²². PGE2 also mediates tissue injury via release of matrix metalloproteinases²³. In a pilot study of patients undergoing chemotherapy, there was a significant association among pain and COX-1 and COX-2 levels, suggesting an important role of cyclooxygenase in oral mucositis, with the increase of pro-inflammatory prostaglandins expression²⁴.

COX-2 is not the primary driver of mucosal injury but intensifies and prolongs mucositis by interacting with a variety of apoptotic pathways and providing positive feedback to nuclear factor kappa B (NF- κ B), one of the main drivers of mucositis¹⁸. In a study

performed to assess the expression of NF- κ B and COX-2 in the oral cavity of patients undergoing cytotoxic chemotherapy treatment, the results showed a significant increase in both NF- κ B and COX-2 post-chemotherapy when compared to the pre-treatment period⁷.

Matrix metalloproteinases (MMPs) are involved in metabolism of extracellular matrix degradation²⁵. ECM protein expression and its effects on cell kinetics were investigated in animals. The findings indicated substantial augmentation in cell kinetics, especially cell cyto-stasis and apoptosis in response to chemotherapeutic treatment in mice with irinotecan at 200 mg / kg. This was accompanied by a decrease in fibronectin early on following treatment and an increase in collagen deposits during the period of maximal damage²⁶. In addition, the changes in ECM were attributed to deregulated expression of MMPs 2, 3, 9 and 12, having a direct impact on the loss of mucosa integrity evident in mucositis²⁷.

Influence of oral microbiota in the development of mucositis

The pathogenesis of mucositis involves a sequence of biological events in association with influences of the oral cavity environment and microbiota with its variety of microorganisms, such as bacteria, viruses and fungi²⁸.

The oral microbiota has unique features and it is modified by the presence of saliva. This fluid is composed of enzymes, antibodies, and proteins that play an important role in maintaining homeostasis of the oral mucosa and limiting microbial colonization. Patients treated with head and neck radiotherapy can suffer from xerostomia, increasing the suspicion that a quantitative or qualitative change of saliva can affect the course of mucositis²⁹.

Mucositis is not considered an infectious disease, even if there is bacterial colonization in specific situations, prior to development. Furthermore, oral mucositis has been identified as an independent risk factor, although it is common to find ulcerative lesions colonization by microbial components which may cause opportunistic infections²⁸. In addition, a chronic inflammatory infiltrate composed of macrophages may be present in advanced stages

of oral mucositis⁵.

The role of viruses, particularly herpes simplex (HSV), as an aggravating agent of radiation-induced mucositis has been confirmed. In a study undertaken to evaluate the relationship between the HSV virus and clinical significant oral mucositis, HSV-1 infection at 29.1% of patients and was observed to aggravate radiation induced oral ulcerative mucositis in these infected subjects. Thus, it suggested that the treatment with standard antiviral therapy affects favorably the subsequent course of mucositis, and although not a primary driver of mucositis, HSV-1 presence as a secondary infection could affect the course of the condition³⁰.

Patients undergoing antineoplastic therapy have a significantly increased risk for the development of fungal infections in the oral cavity. For patients receiving radiation therapy to the head and neck and patients undergoing chemotherapy (primarily for hematologic tumors), the prevalence of oral fungal infection in observational studies was 37.4% and 38%, respectively. Additionally, lesions arising from oral mucositis can reduce the patient's ability to maintain oral hygiene which in turn may increase the risk for oral candidiasis. Thus, systemic antifungal prophylaxis is recommended in highly immunosuppressed patients and can be expected to be effective against oral fungal infection³¹.

IMMUNOPATHOLOGY OF MUCOSITIS

Although the development of oral mucositis is a dynamic process, Sonis in 2004¹⁸, proposed a division of its biological development in five phases: initiation, message generation, signaling and amplification, ulceration and healing, which are illustrated schematically in figures 1 and 2.

Initiation

The initiation stage of tissue injury occurs rapidly following the exposure to radiation or administration of chemotherapy, providing a direct damage to the DNA of some cells at the basal epithelium as well as cells within the submucosa, resulting in the rapid break off of a small number of cells. Simultaneously, reactive oxygen species (ROS) are generated, triggering a series of biological events^{2,18}. In addition, the cells

damaged by radiation and chemotherapy may release endogenous damage-associated pattern molecules (CRAMPs), which then bind to specific receptors and contribute to the activation of the innate immune response and initiation of the second stage²⁹. Although the mucosa seems to be absolutely normal at this stage, a cascade of events begins in the submucosa³.

Message generation

During the second phase, multiple events occur simultaneously². Radiation, chemotherapy, and ROS effectively activate a number of central biological control mechanisms, including a select group of transcription factors¹⁸. Among these, probably one of the most important for the development of mucositis is NF- κ B, because once activated, it moves to the nucleus, where it is capable of upregulating up to 200 genes, including genes that code for pro-inflammatory cytokines, such as TNF- α , IL-1 β and IL-6, addition of adhesion molecules. In addition, NF-

κ B also impacts genes of the BCL2 family, providing a mechanism whereby induction of NF- κ B can directly promote apoptosis⁵. Upregulation of other genes causes the expression of adhesion molecules, subsequent activation of the cyclooxygenase-2 pathway, and consequent angiogenesis².

Other transcription factors are also activated, and each is associated with the expression of genes and its associated biologically active proteins¹⁸. Both sphingomyelinase and ceramide synthase are activated by neoplastic therapy to initiate apoptosis mediated by the ceramide pathway. Also, fibroblasts are damaged directly through radiation or chemotherapy and indirectly injury by activating protein 1 (AP1) pathway which stimulate the secretion of MMP. Metalloproteinases produce injury within the tissues of the submucosa and disrupts the integrity of the interface between the epithelium and submucosa at the basement membrane⁵. Macrophages are subsequently activated, leading to tissue injury through MMP and additional production of TNF- α ².

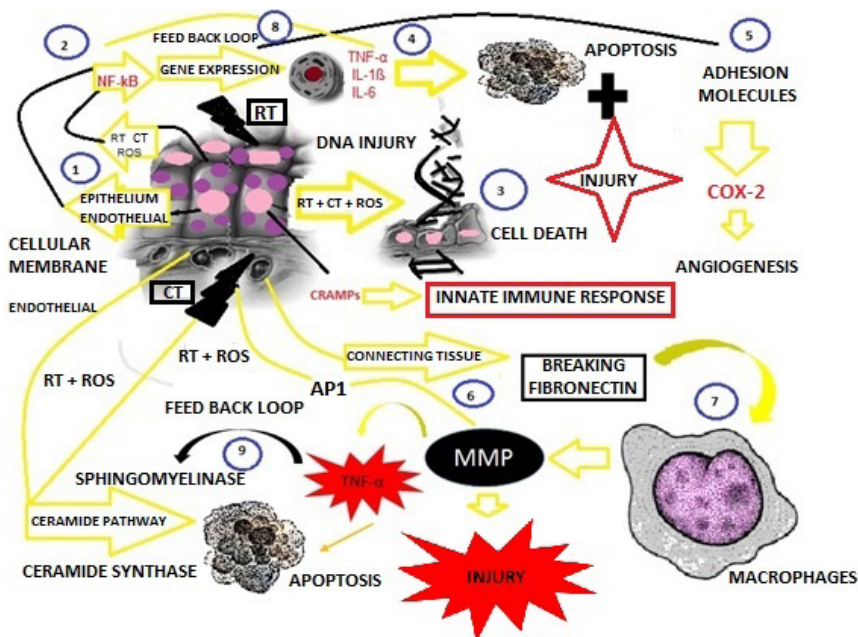


Figure 1. (Phase initiation, message generation and signaling / amplification of oral mucositis - adaptation of Sonis 2004): Chemotherapy (CT) or radiotherapy (RT) may initiate mucositis directly by causing DNA strand breaks, through the generation of reactive oxygen species (ROS) and subsequent activation of transcription factors (1). ROS may damage other cells and tissues directly and also stimulate secondary mediators of injury, including such transcription factors as nuclear factor κ B (NF- κ B) (2). In the next phase, message generation, multiple events occur simultaneously. ROS cause DNA damage, resulting in cell death (3). Activation of transcription factors in response to ROS, RT, or CT results in gene up-regulation, including the genes TNF- α , IL-1 and IL-6, leading to tissue injury and apoptosis of cells within the submucosa and primary injury of cells within the basal epithelium (4). Other genes also are up-regulated, leading to the expression of adhesion molecules, COX-2, and subsequent angiogenesis. (5). In addition, the antineoplastic therapy activates protein 1 (AP1), stimulating the secretion of matrix metalloproteinases (MMPs) (6). Macrophages are activated, leading to production of MMPs and an increase in TNF- α production by promoting direct tissue injury (7). During the signaling and amplification phase, one consequence of the flood of mediators released in response to the initial insult is a series of positive feedback loops that serve to amplify and prolong tissue injury through their effects on transcription factors (8) and on the ceramides (9).

Signaling and amplification

It seems likely that, in addition to exerting a direct damaging effect on mucosal target cells, pro-inflammatory cytokines also play an indirect role in amplifying and signaling mucosal injury initiated by radiation and chemotherapy^{2,5}. For example, TNF- α is a very capable activator of a number of pathways that can lead to tissue injury, including the ceramide and caspase pathways and the transcription pathway mediated by NF- κ B. This signaling process may lead to increased production of pro-inflammatory cytokines such as TNF- α , IL-1 β and IL-6. Thus, its presence in tissue serves, through a positive feedback loop, to potentiate the activity of these two controlling mechanisms following the initial

insult².

Other cytokines, such as IL-17 and IL-22 may be related to oral mucositis, although there is no scientific evidence at this given time. Studies suggest that IL-17 produced by cells induces the production of pro-inflammatory cytokines such as IL-1, IL-6 and TNF- α , and certain chemokines and adhesion molecules, thus leading to cell recruitment, inflammatory response and interaction of cells with the epithelium. Thus, IL-17 enhances the local inflammatory process, particularly by modulation of neutrophil activity. Recently there was a significant positive correlation between the area of periodontal lesions and serum levels of IL-17³³. The IL-22 expression has been reported in numerous human diseases and modulates the

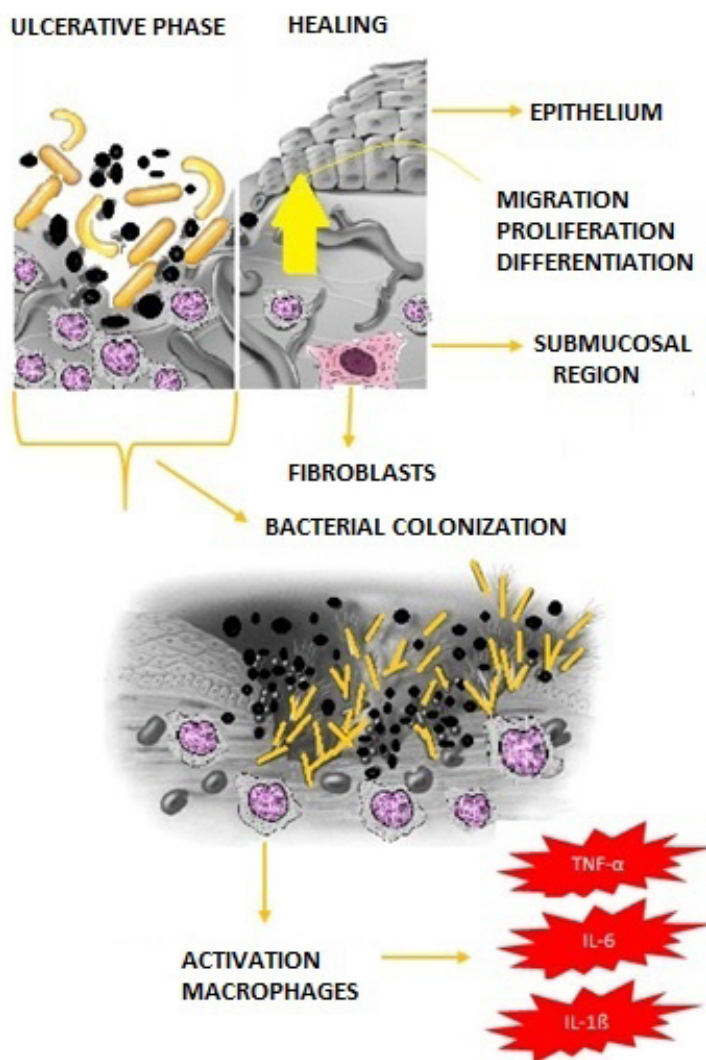


Figure 2. (Ulceration and healing phase of oral mucositis - adaptation of Sonis 2004): Ulcerative phase is characterized by complete epithelial destruction. The ulcer serves as a focus for gram-positive, gram-negative and anaerobic colonization. Secondary infection by other microorganisms is quite common at this stage. Cell wall products from bacteria penetrate the submucosa by stimulating infiltrating macrophages to produce and release additional proinflammatory cytokines (TNF- α , IL-6 e IL-1 β), and further exacerbate the condition. In neutropenic patients, whole bacteria may invade submucosal vessels and cause bacteremia or sepsis. Spontaneous healing occurs through a dynamic process between the extracellular matrix and the epithelium of the oral cavity.

mucosal immune response. Functional studies suggest that this cytokine has immunomodulatory properties in infection, inflammation, autoimmunity, and cancer. The functional consequences of IL-22 expression can be pathological or protection, depending on the context in which it is expressed³⁴.

It is noteworthy that while biological damage occurs during the initial phases of mucositis, the clinical picture is quiescence. Although there might be some mucosal erythema during these stages, for the most part, tissue integrity is preserved and patients have few symptoms³.

Ulceration

The ulcerative phase of mucositis is, of course, the most clinically significant and is responsible for the pain and loss of function. The ulcers of oral mucositis are characterized by their depth and wandering confluence as well as by the presence of a fibrinous exudate¹⁸. Microscopically, the exudate is characterized by a robust inflammatory infiltrate comprised of both mono and polymorphonuclear cells, of which the most common are macrophages².

During the ulcerative phase of mucositis, bacterial colonization occurs with gram-positive, gram-negative, and anaerobic organisms. Cell wall products from bacteria can activate tissue macrophages, leading to more production of pro-inflammatory cytokines². In neutropenic patients, these breaks in mucosa serve as portals of entry for the innumerable microorganisms that reside in the mouth, and often lead to bacteraemia and sepsis³.

Healing

In the last stage, ulcers heal spontaneously, although this process is also biologically dynamic¹⁸. Signals from the submucosal ECM and mesenchyme govern the rate of epithelial-cell migration, the rate of proliferation and the differentiation of healing tissue³. Additionally, there is the reestablishment of the local microbial flora². After the healing phase, the oral mucosa appears normal; however, despite its normal appearance, the mucosal environment has been significantly altered. There is residual angiogenesis, and the patient is now at increased risk of future episodes of oral mucositis and its

complications during continuous anticancer therapy².

THERAPEUTIC ALTERNATIVES AND THEIR IMPLICATIONS

Good oral hygiene habits associated with a satisfactory dental condition may reduce the risk, course, and severity of oral mucositis. Although oral mucositis is not an infectious condition, microorganisms may colonize the ulcers and prolong the healing time.

As such, it is important to reduce the oral bacterial load through a good oral hygiene. In addition, any possible irritant such as ill-fitting dentures or orthodontic appliances should be adjusted or removed during antineoplastic treatment³⁵. The Multinational Association of Supportive Care in Cancer (MASCC) and International Society of Oral Oncology (ISOO) suggests the use of oral care protocols for the prevention of oral mucositis across all cancer treatment modalities.

These protocols typically included a combination of tooth brushing, flossing, and daily mouth rinses to maintain oral hygiene³⁶. (Table 1).

Palifermin (keratinocyte growth factor-1) is the only agent that has been approved as a drug by the US Food and Drug Administration and the European Medicines Agency for oral mucositis. It has the ability to reduce the radiation-induced mucosal damage due, in part, to its effect on glutathione activity. Additionally, it upregulates Nrf2 reducing the oxygen-free radical damage and preventing DNA strand breaks through its antiapoptotic effects^{32,37-38}. MASCC / ISOO recommends the use of palifermin preemptively by patients receiving high-dose chemotherapy and total body irradiation followed by autologous stem cell transplantation for hematological malignancies³⁶.

N-acetyl cysteine is an antioxidant with the power to affect NF- κ B. A recent study showed efficacy in humans, through its administration via the parenteral route. N-acetylcysteine, at a dose of 100mg/kg/day, was effective in reducing the incidence and the total duration of severe cases of oral mucositis in patients submitted to leukemia stem cell transplantation³⁹.

Table 1. Major therapeutic agents used for the prevention or treatment of oral mucositis (MASCC/ISOO Clinical Practice Guidelines for Oral Mucositis).

AGENT	PROTOCOL MASCC/ISOO	ANTINEOPLASTIC TREATMENT
Oral hygiene (brushing, flossing and mouthwash 1x daily)	Suggested for prevention	All modalities (HSCT, H&NRT, CT)
Palifermin	Insufficient data	HSCT
N-acetyl cysteine	No approach	No approach
Benzydamine hydrochloride	Recommended for prevention	H&NRT
Nystatin and Acyclovir	Insufficient data	All modalities
Antimicrobials lozenge (polymyxin, tobramycin, amphotericin, bacitracin, clotrimazole and gentamicina)	NOT recommended	HSCT
Antimicrobials paste (polymyxin, tobramycin and amphotericin)	NOT recommended	HSCT
Chlorhexidine mouthwash	NOT suggested for prevention	H&NRT
Topical anesthetic	Insufficient data	All types
Intravenous morphine	Recommended for treatment	HSCT
2% solution of morphine	Suggested for treatment	H&NRT
Cryotherapy	Recommended for prevention Suggested for prevention	CT WITH 5-FU HSCT
Zinc	Suggested for prevention	H&NRT with CT
Vitamin A, E, honey, aloe vera, chamomile tea, chinese herbes	Insufficient data	Insufficient data
LLL	Recommended for prevention Suggests to prevent	HSCT H&NRT

* Table 1 Codes: MASCC/ISOO (Multinational Association of Supportive Care in Cancer and International Society of Oral Oncology). HSCT (hematopoietic stem cell transplantation). H&NRT (head and neck radiotherapy). CT (chemotherapy). 5-FU (5- fluorouracil). LLLT (low level laser therapy).

** The term "Recommends " addresses therapeutic agents with extensive scientific evidence. The term "Suggests " depicts the agents with restricted evidence in the literature.

Benzylamine hydrochloride is a nonsteroidal compound for topical use which has analgesic and anti-inflammatory effect, and plays a vital role in combating the pathogenesis of oral mucositis radiation by inhibiting production of pro-inflammatory cytokines, including IL-1 β and TNF- α . Existing studies suggest Benzylamine may benefit patients at risk for radiation-induced mucositis in patients receiving doses above 50 Gy. When combined however with standard chemotherapy, this treatment has no effect^{36,40}.

Several topical antimicrobial agents have been examined for the treatment of oral mucositis, including antibacterial, antiviral and antifungal agents. Current evidence supports a recommendation against the use of lozenges containing polymyxin, tobramycin, and amphotericin and bacitracin, clotrimazole, and^{36,41}. Additionally, pastes containing amphotericin, polymyxin and tobramycin are also not recommended for the prevention of oral mucositis in patients receiving high doses of chemotherapy and total-body irradiation followed by autologous stem cell transplantation³⁶. Due to the conflicting results and the difficulty of clinically separating viral and fungal lesions from toxicity-induced mucositis and insufficient evidence, no guideline exists for the use of acyclovir and nystatin in preventing^{36,41}. It is recognized however that acyclovir is useful in preventing recurrent herpetic lesions in HSV seropositive patients undergoing highly immunosuppressive chemotherapy⁴¹.

Chlorhexidine has been researched for mucositis as well. To date, no guideline exists for the use of chlorhexidine mouthwash in the prevention or treatment of oral mucositis due to the insufficient and/or conflicting evidence. One cannot discount the use of chlorhexidine as an effective antiplaque agent in the role oral decontamination⁴¹. MASCC/ISOO does not suggest the use of chlorhexidine mouthwash for the prevention of oral mucositis in patients receiving radiotherapy³⁶.

Although the use of topical anesthetic agents is very common in patients with oral mucositis, studies of such agents in isolation are limited. These agents are generally tested in combination with anti-inflammatory and antimicrobial rinses, making it difficult to determine the potential benefit of each

of the therapeutic components. Few existing studies of topical anesthetics alone, demonstrate a transitory benefit with regards to pain relief of oral mucositis, making systemic analgesia necessary for pain control. More studies of topical anesthetics in isolation are warranted to obtain more conclusive results⁴¹.

Systemic analgesics, including opioids, are used clinically for pain management in most patients with severe oral mucositis due to its high capacity to reduce the acute pain sensation. However, these agents have significant side effects and efficacy can vary by medication, dose, and route of administration. With regards to hospitalized patients undergoing stem cell transplantation, the evidence supports a recommendation in favor the use of IV morphine. Due to the side effects associated with the systemic use of opioids, there has been increasing interest in the use of these agents topically in the oral cavity⁴¹. Although studies with such topical use of opioids were limited, the data does suggest benefit in the use of a 2 % morphine rinse in radiation-induced oral mucositis in head and neck patients^{36,41}.

Cryotherapy is a therapeutic technique which consists in the use of ice to control pain and inflammation. Existing evidence supports the efficacy of this technique in the prevention of oral mucositis. The use of cryotherapy is recommended for the prevention of oral mucositis in patients receiving bolus dosing of 5-fluorouracil as well as in patients undergoing stem cell transplant conditioning regimen³⁶.

Studies of natural agents are rare in the literature. Currently, the use of zinc is suggested for patients with oral cancer undergoing radiotherapy or chemoradiation. Studies of other natural agents, such as vitamin A, vitamin E, honey, chamomile tea, Aloe Vera and Chinese herbs present inadequate and/or conflicting evidence in regards to the effectiveness of these agents in preventing oral mucositis. Further studies are required before recommendations can be made for or against the use of these agents³⁶.

Presently, there is no therapy can completely prevent oral mucositis. Low-level laser therapy (LLLT) is considered a promising therapy for disease resolution, due to its analgesic, anti-inflammatory and healing effects. A recent study showed its

contribution to the reduction of inflammation and severity of oral mucositis in patients with head and neck cancer undergoing simultaneously radiotherapy and chemotherapy⁴². In addition, another study evaluated the efficacy of laser in the prevention of oral mucositis in patients undergoing chemotherapy and radiotherapy, as well as in the prevention of painful symptoms associated with this condition. The results showed that LLLT retards the development and evolution of mucositis and demonstrated a statistically significant ($p = 0.004$) effect in pain control⁴³. In the clinical practice guidelines for the management of mucositis secondary to cancer therapy, MASCC / ISOO (2014), LLLT (wavelength 650 nm, 40 mW power and energy per point 2 J / cm²), is now recommended for the prevention of oral mucositis in patients receiving high-dose chemotherapy for stem cell transplant with or without total body irradiation. LLLT (wavelength 632.8 nm) is also suggested for the prevention of oral mucositis in patients receiving radiotherapy in the head and neck without concomitant chemotherapy³⁶.

CONCLUSION

Oral mucositis is a common and clinically significant complication of antineoplastic therapy. Although this disease is associated with a small group of patients, its impact can negatively affect the patient quality of life and compromise the proposed therapy, or even result in its interruption.

The biological complexity of this dynamic process makes it difficult to establish a fully effective therapeutic agent. Significant advances in the knowledge of the immunopathology of oral mucositis will promote the prevention and treatment in all stages of development of this clinical condition. Thus, queries related to the molecular interactions and biological events of mucositis, as well as those that include the study of the specific toxicity of the drugs used in antineoplastic therapy, become relevant as they may stimulate the discovery and implementation of effective interventions for oral mucositis.

ACKNOWLEDGEMENTS

This study was sponsored by a grant (REDE- 0025) from the State Research Support Foundation of Bahia (Fundação de Amparo à Pesquisa do Estado da Bahia - FAPESB in the Brazilian acronym).

AUTHOR CONTRIBUTIONS

Dantas JBL participated in the writing of the text. Martins GB participated in the translation of the article and critical review. Lima HR collaborated in the article review assay and critical review. Carrera M contributed in the English proofreading and critical review. Reis S contributed to English review. Medrado A guided all stages of the work and participated in the review and writing of the article.

COMPETING INTERESTS

No financial, legal or political competing interests with third parties (government, commercial, private foundation, etc.) were disclosed for any aspect of the submitted work (including but not limited to grants, data monitoring board, study design, manuscript preparation, statistical analysis, etc.).

REFERENCES

1. Scully C, Epstein J, Sonis ST. Oral mucositis: a challenging complication of radiotherapy, chemotherapy, and radiochemotherapy. Part 2: diagnosis and management of mucositis. *Head Neck*. 2004;26(1):77–84. doi: [10.1002/hed.10326](https://doi.org/10.1002/hed.10326)
2. Sonis ST, Elting LS, Keefe D, Peterson DE, Schubert M, Hauer-Jensen M et al. Perspectives on cancer therapy-induced mucosal injury: pathogenesis, measurement, epidemiology, and consequences for patients. *Cancer*. 2004;100(9 Suppl):1995-2025. doi: [10.1002/cncr.20162](https://doi.org/10.1002/cncr.20162)
3. Sonis ST. The pathobiology of mucositis. *Nat Rev*. 2004;4(4):277-284. doi: [10.1038/nrc1318](https://doi.org/10.1038/nrc1318)
4. Sonis ST, Lindquist L, Van Vugt A, Stewart AA, Stam K, Qu GY et al. Prevention of chemotherapy-induced ulcerative mucositis by transforming growth factor β 3. *Cancer Res*. 1994;54:1135-38
5. Sonis ST. Pathobiology of oral mucositis: novel insights and opportunities. *J Support Oncol*. 2007;5(9):3–11
6. Sonis ST. New thoughts on the initiation of mucositis. *Oral Diseases*. 2010;16(7):597–600. doi: [10.1111/j.1601-0825.2010.01681.x](https://doi.org/10.1111/j.1601-0825.2010.01681.x)
7. Logan RM, Gibson RJ, Sonis ST, Keefe DMK. Nuclear factor-Kb and cyclooxygenase – 2 (COX-2) expression in the oral mucositis following cancer chemotherapy. *Oral Oncol*. 2007;43(4):395-401. doi: [10.1016/j.oraloncology.2006.04.011](https://doi.org/10.1016/j.oraloncology.2006.04.011)

8. Larjava H, Koivisto L, Häkkinen L, Heino J. Epithelial Integrins with Special Reference to Oral Epithelia. *J Dent Res.* 2011;90(12):1367-1376. doi: [10.1177/0022034511402207](https://doi.org/10.1177/0022034511402207)
9. Al-Dasooqi N, Sonis ST, Bowen JM, Bateman E, Blijlevens N, Gibson RJ et al. Emerging evidence on the pathobiology of mucositis. *Supp Care Cancer.* 2013;21(7):2075-2083. doi: [10.1007/s00520-013-1810-y](https://doi.org/10.1007/s00520-013-1810-y)
10. Al-Sadi R, Ye D, Said HM, Ma TY. IL-1beta-induced increase in intestinal epithelial tight junction permeability is mediated by MEKK-1 activation of canonical NF-kappaB pathway. *Am J Pathol.* 2010;177(5): 2310-2322. doi: [10.2353/ajpath.2010.100371](https://doi.org/10.2353/ajpath.2010.100371)
11. Al-Sadi R, Ye D, Dokladny K, Ma TY. Mechanism of IL-1beta-induced increase in intestinal epithelial tight junction permeability. *J Immunol.* 2008;180(4):5653-5661
12. Colley HE, Eves PC, Pinnock A, Thornhill MH, Murdoch C. Tissue-engineered oral mucosa to study radiotherapy-induced oral mucositis. *Int Jour of Rad Bio.* 2013;89(11):907-914. doi: [10.3109/09553002.2013.809171](https://doi.org/10.3109/09553002.2013.809171)
13. Gonzalez VM, Fuertes MA, Alonso C, Perez JM. Is Cisplatin-Induced Cell Death Always Produced by Apoptosis? *Mol Pharmacol.* 2001;59(4):657-663
14. Kerr JFR. History of the events leading to the formulation of the apoptosis concept. *Toxicology.* 2002;471-74
15. Sonis ST, Costa JW, Evitts SM, Lindquist, LE, Nicolson M. Effect of epidermal growth factor on ulcerative mucositis in hamsters that receive cancer chemotherapy. *Oral Surg Oral Med Oral Pathol.* 1992; 74(6):749-55
16. Gibson R, Cummins AG, Bowen JM, Logan RM, Healey T, Leefe DM. Apoptosis occurs early in the basal layer of the oral mucosa following cancer chemotherapy. *Asia Pac J Clin Oncol.* 2006;2(1):39-49. doi: [10.1111/j.1743-7563.2006.00038.x](https://doi.org/10.1111/j.1743-7563.2006.00038.x)
17. Hwang D, Popat R, Bragdon C, O'Donnell KE, Sonis ST. Effects of ceramide inhibition on experimental radiation-induced oral mucositis. *Oral Surg Oral Med Oral Pathol Oral Radiol Endod.* 2005;100(3):321-9. doi: [10.1016/j.tripleo.2004.09.018](https://doi.org/10.1016/j.tripleo.2004.09.018)
18. Sonis ST. A biological approach to mucositis. *J Support Oncol.* 2004;2(1):21-36
19. Morales-Rojas T, Vieira N, Morón-Medina A, Álvarez A. Proinflammatory cytokines during the initial phase of oral mucositis in patients with acute lymphoblastic leukaemia. *Int Journal of Paed Dent.* 2012;22(3):191-96. doi: [10.1111/j.1365-263X.2011.01175.x](https://doi.org/10.1111/j.1365-263X.2011.01175.x)
20. Citrin DE, Hitchcock YJ, Chung EJ, Frandsen J, Urick ME, Shield W et al. Determination of cytokine protein levels in oral secretions in patients undergoing radiotherapy for head and neck malignancies. *Rad Onco.* 2012;64(7):1-6. doi: [10.1186/1748-717X-7-64](https://doi.org/10.1186/1748-717X-7-64)
21. Meirovitz A, Kuten M, Billan S, Abdah-Bortnyak R, Sharon A, Peretz T et al. Cytokines levels, Severity of acute mucositis and the need of PEG tube installation during chemo-radiation for head and neck cancer a prospective pilot study. *Rad Onco.* 2010;16(5):1-7. doi: [10.1186/1748-717X-5-16](https://doi.org/10.1186/1748-717X-5-16)
22. Lin CR, Amaya F, Barrett L, Wang H, Takada J, Samad TA et al. Prostaglandin E2 receptor EP4 contributes to inflammatory pain hypersensitivity. *J Pharmacol Exp Ther.* 2006;319(3):1096-1103. doi: [10.1124/jpet.106.105569](https://doi.org/10.1124/jpet.106.105569)
23. Shankavaram UT, Lai WC, Netzel-Arnett S, Mangan PR, Ardans JA, Caterina N et al. Monocyte membrane type 1-matrix metalloproteinase. Prostaglandin-independent regulation and role in metalloproteinase-2 activation. *J Biol Chem.* 2001;276(22):19027-19032. doi: [10.1074/jbc.M009562200](https://doi.org/10.1074/jbc.M009562200)
24. Lalla RV, Pilbeam CC, Walsh SJ, Sonis ST, Keefe DMK, Peterson DE. Role of the cyclooxygenase pathway in chemotherapy-induced oral mucositis: a pilot study. *Supp Care Cancer.* 2010;18(1):95-103. doi: [10.1007/s00520-009-0635-1](https://doi.org/10.1007/s00520-009-0635-1)
25. Singh D, Srivastava SK, Srivastava TK, Upadhyay G. Multifaceted role of matrix metalloproteinases (MMPs). *Front. Mol. Biosci.* 2015;2:19; doi: [10.3389/fmolb.2015.00019](https://doi.org/10.3389/fmolb.2015.00019)
26. Al-Dasooqi N, Bowen JM, Gibson RJ, Logan RM, Stringer AM, Keefe DM. Irinotecan-induced alterations in intestinal cell kinetics and extracellular matrix component expression in the dark agouti rat. *Int.J.Exp.Path.* 2011; 92:357-365. doi: [10.1111/j.1365-2613.2011.00771.x](https://doi.org/10.1111/j.1365-2613.2011.00771.x)
27. Al-Dasooqi N, Gibson RJ, Bowen JM, Logan RM, Stringer AM, Keefe DM. Matrix metalloproteinases are possible mediators for the development of alimentary tract mucositis in the dark agouti rat. *Exp Biol Med.* 2010;235(10):1244-1256. doi: [10.1258/ebm.2010.010082](https://doi.org/10.1258/ebm.2010.010082)
28. Sonis ST. Mucositis: the impact, biology and therapeutic opportunities of oral mucositis. *Oral Oncol.* 2009;45(12):1015-1020. doi: [10.1016/j.oraloncology.2009.08.006](https://doi.org/10.1016/j.oraloncology.2009.08.006)
29. Scaratino C, LeVeque F, Swann RS, White R, Schulsinger A, Hodson I et al. Effect of pilocarpine during radiation therapy: results of RTOG97-09, a phase III randomized study in head and neck cancer patients. *J Support Oncol.* 2006;4(5):252-258
30. Nicolatou-Galitis O, Athanassiadou P, Kouloulis V, Sofiropoulou-Lontou A, Dardoufas A, Polychronopoulou A et al. Herpes simplex virus-1 (HSV-1) infection in radiation-induced oral mucositis. *Support Care Cancer.* 2006;14(7):753-762. doi: [10.1007/s00520-005-0006-5](https://doi.org/10.1007/s00520-005-0006-5)

31. Lalla RV, Latortue MC, Hong CH, Ariyawardana A, D'Amato-Palumbo S, Fischer DJ et al. A systematic review of oral fungal infections in patients receiving cancer therapy. *Support Care Cancer*. 2010;18(8):985–992. doi: [10.1007/s00520-010-0892-z](https://doi.org/10.1007/s00520-010-0892-z)
32. Villa A, Sonis ST. Mucositis: pathobiology and management. *Curr Opin Oncol*. 2015;27(3):159–164. doi: [10.1097/CCO.000000000000180](https://doi.org/10.1097/CCO.000000000000180)
33. Herane A, Chaparro A, Quintero A, Sanz A, Hernández M, Gaedechens M et al. Expresión de citoquinas Th17 y su correlación con periodontopatógenos y el área periodontal inflamada en pacientes con periodontitis crónica. *Rev. Clin Periodoncia Implantol Rehabil Oral*. 2013;6(3):109-113. doi: [10.4067/S0719-01072013000300001](https://doi.org/10.4067/S0719-01072013000300001)
34. Sonnenberg GF, Fouser LA, Artis D. Functional Biology of the IL-22-IL-22R Pathway in Regulating Immunity and Inflammation at Barrier Surfaces. *Advances in Immunology*. 2010;107:1-29. doi: [10.1016/B978-0-12-381300-8.00001-0](https://doi.org/10.1016/B978-0-12-381300-8.00001-0)
35. Keefe DM, Schubert MM, Elting LS, Sonis ST, Epstein JB, Raber-Durlacher JE et al. Updated clinical practice guidelines for the prevention and treatment of mucositis. *Cancer*. 2007;109(5):820–831. doi: [10.1002/cncr.22484](https://doi.org/10.1002/cncr.22484)
36. Lalla RV, Bowen J, Barasch A, Elting L, Epstein J, Keefe DM et al. MASCC/ISOO Clinical practice guidelines for the management of mucositis secondary to cancer therapy. *Cancer*. 2014;120(10):1453-1561. doi: [10.1002/cncr.28592](https://doi.org/10.1002/cncr.28592)
37. Sonis ST. Efficacy of palifermin (keratinocyte growth factor-1) in the amelioration of oral mucositis. *Core Evidence*. 2009;4:199-205
38. Yuan A, Sonis ST. Emerging therapies for the prevention and treatment of oral mucositis. *Expert Opin Emerging Drugs*. 2014;19(3):1-9
39. Moslehi A, Taghizadeh-Ghehi M, Gholami K, Hadjibabaie M, Jahangard-Rafsanjani Z, Sarayani A et al. Bone Marrow Transplantation. 2014;49(6):818–823. doi: [10.1038/bmt.2014.34](https://doi.org/10.1038/bmt.2014.34)
40. Epstein EB, Silverman Jr S, Paggiarino DA, Crockett S, Schubert MM, Senzer NN et al. Benzydamine HCl for Prophylaxis of Radiation-Induced Oral Mucositis Results from a Multicenter, Randomized, Double-Blind, Placebo-Controlled Clinical Trial. *Cancer*. 2001;92(4):875-885
41. Saunders DP, Epstein JB, Elad S, Allemanno J, Bossi P, Van de Wetering MD et al. Systematic review of antimicrobials, mucosal coating agents, anesthetics, and analgesics for the management of oral mucositis in cancer patients. *Support Care Cancer*. 2013;21(11):3191-3207. doi: [10.1007/s00520-013-1871-y](https://doi.org/10.1007/s00520-013-1871-y)
42. Oton-Leite AF, Silva GBL, Morais MO, Silva TA, Leles CR, Valadares MC et al. Effect of low-level laser therapy on chemoradiotherapy-induced oral mucositis and salivary inflammatory mediators in head and neck cancer patients. *Lasers in Surg and Med*. 2015;47(4):296–305. doi: [10.1002/lsm.22349](https://doi.org/10.1002/lsm.22349)
43. Carvalho PAG, Jaguar GC, Pellizzon AC, Prado JD, Lopes RN, Alves FA. Evaluation of low-level laser therapy in the prevention and treatment of radiation-induced mucositis: A double-blind randomized study in head and neck cancer patients. *Oral Oncology*. 2011;47(12):1176-1181. doi: [10.1016/j.oraloncology.2011.08.021](https://doi.org/10.1016/j.oraloncology.2011.08.021)