

# POSTVACCINATION TRANSVERSE MYELITIS IN THE POSTPARTUM PERIOD: CASE REPORT AND LITERATURE REVIEW

*Orivaldo Alves Barbosa\**, *Anna Dorotheia Bezerra de Souza\*\**, *Cristiane Souza Vasconcelos\*\*\**,  
*Paola Lima Lemos\*\*\*\**

---

Corresponding author: Orivaldo Alves Barbosa - orivaldo.barbosa@yahoo.com.br

\*Medicine Professor at Unichristus, Fortaleza, Ceará, Brazil

\*\*Obstetrics Department, Physician at the General Hospital Cesar Cals, Fortaleza, Ceará, Brazil

\*\*\*Internal Medicine Department, Cesar Cals General Hospital, Fortaleza, Ceará, Brazil

\*\*\*\*Physician at the General Hospital Cesar Cals, Fortaleza, Ceará, Brazil

---

## ABSTRACT

---

Transverse myelitis (TM) is a clinical syndrome in which an inflammatory process injures the spinal cord potentially resulting in weakness, sensory abnormalities and autonomic dysfunction. The main causes are post-infectious, post-vaccination, autoimmune and demyelinating diseases. In a literature review based on five cases of TM during pregnancy and puerperal period have been reported. We report a female patient in the immediate postpartum period who presented acute transverse myelitis after receiving double viral vaccine (measles and rubella). After exclusion of other causes, patient received methylprednisolone in high doses ( 1000 mg for 3 consecutive days) and had complete clinical reversal. Thus it is intended to report this rare occurrence which is post-vaccination TM in the postpartum period.

**Keywords:** Transverse Myelitis; Postpartum

## INTRODUCTION

Transverse myelitis (TM) is a rare syndrome that presents with neurological deficits secondary to an inflammatory process that causes lesions, acute or subacute, in the spinal cord potentially resulting in weakness, sensorial alterations and autonomic dysfunction<sup>1</sup>.

Incidence of transverse myelitis range from 1.3 to 8 cases per million, there is a bimodal peak in the incidence at 10 to 19 years of age and at 30 to 39 years<sup>2</sup>. Transverse myelitis syndrome arise from various causes, but it most often occurs as an autoimmune phenomenon after an infection or vaccination<sup>3</sup>. In pregnancy and puerperium few cases of TM are reported, mostly related to epidural anesthesia<sup>4,5</sup>.

The publication of this case has been authorized by patient and family, and the text submitted for approval by the ethics committee on research Hospital Cesar Cals, with favorable report number 1.603.060, according to the Resolution 466 of the National Health Council (CNS).

## CASE REPORT

Patient 18 was admitted to the emergency department at gestational ages of 36 weeks featuring hypertension (200x120mmHg) associated with headache in occipital region and proteinuria. On the second day of hospitalization, after stabilization, cesarean section was performed through a transverse incision of the lower uterine segment, and a healthy infant was delivered. After giving birth, became asymptomatic with good blood pressure control. On the third postoperative day received double viral vaccine (measles and rubella) to update the vaccination calendar. On the fourth day developed rapidly progressive paraparesia of the lower limbs, associated with sensitive level (T4), hyperreflexia, ankle clonus, bilateral Babinsk signal and autonomic dysfunction.

MRI of the entire spine, with and without gadolinium

was performed to evaluate for compressive versus noncompressive cord lesion, indicating discrete signal changes, affecting the posterolateral aspect of the central marrow, in the level of T4 and T3-T4-T5 without contrast enhancement suggesting transverse myelitis (figure1).

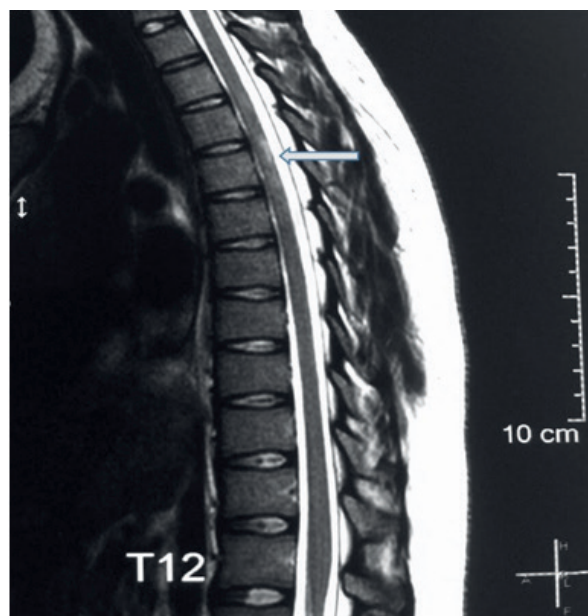


Figure 1. MRI of Thoracic Spine evidencing signal changes, affecting the posterolateral aspect of the central marrow, in the level of T4 (Arrow).

Cerebrospinal fluid analysis was performed, including cell count and differential, protein, glucose, VDRL, oligoclonal bands, immunoglobulin G index, and cytology. Serum was analysed for the presence of NMO-IgG antibodies (anti-aquaporin-4 IgG), B12, methylmalonic acid, human immunodeficiency antibodies, syphilis serologies, serum ANA, Ro/SSA, and La/SSB antibodies (Table 1). After extensive investigation, not being found secondary causes of TM, we considered the diagnosis of post-vaccination myelitis. The patient received treatment with high dose corticosteroids (1000 mg methylprednisolone) for 3 days. The patient had a good response, with full recovery of strength, sphincter control and sensitive symptoms. It was discharged 23 days after the event for outpatient follow.

Table 1. Laboratory data.

Exam	On Presentation	Reference Range
Hemoglobin	12g/dL	12-16g/dL
Leukocyte	12.420/mm <sup>3</sup>	4.000-10.000/mm <sup>3</sup>
Lymphocytes	1989/mm <sup>3</sup>	800-4.500/mm <sup>3</sup>
Platelets	325.000/mm <sup>3</sup>	150.000-450.000/mm <sup>3</sup>

Table 1. Laboratory data. (continued)

Exam	On Presentation	Reference Range
C-reactive protein	125,5mg/L	<5,0mg/L
Cyanocobalamin	293pg/mL	187 a 883pg/mL
Complement C3	155mg/dL	90-180mg/dL
Complement C4	47,6mg/dL	10-40ng/dL
Anti-HIV I and II	nonreactive	nonreactive
VDRL	nonreactive	nonreactive
HBsAg	nonreactive	nonreactive
Anti-HCV	nonreactive	nonreactive
HTLV I and II	nonreactive	nonreactive
Anti-Ro	nonreactive	nonreactive
Beta-2-glycoprotein I IgG	undetermined	-
Beta-2-glycoprotein I IgM	nonreactive	nonreactive
Lupus anticoagulant	nonreactive	nonreactive
Anticardiolipin IgM	nonreactive	nonreactive
Anticardiolipin IgG	nonreactive	nonreactive
ANA	nonreactive	nonreactive
Glucose (cerebrospinal fluid)	61mg/dl	40-74mg/dL
Total protein (cerebrospinal fluid)	10mg/dl	15-45mg/dL
Leukocyte (cerebrospinal fluid)	9/mm <sup>3</sup>	0-5cels/mm <sup>3</sup>
Oligoclonal bands (cerebrospinal fluid)	absent	absent

## DISCUSSION

The TM arise from various causes, most often occurring as an autoimmune phenomenon after an infection or vaccination (accounting for 60% of the cases) or as a result of an underlying systemic autoimmune disease, or an acquired demyelinating disease such as multiple sclerosis or related to neuromyelitis optica<sup>6</sup>.

In literature, there are few reported cases of TM in pregnancy or puerperium<sup>4,5,7-9</sup>, caused by epidural anesthesia in 40%, lupus erythematosus 20%, schistosomiasis 20% and idiopathic in 20%. All patients received steroids in high doses achieving partial or complete response in 80%.

Table 2. Reported Cases of TM in pregnancy and puerperium.

Author	Gestational Age	Cause of TM	Treatment	Outcome
Marabani et al <sup>7</sup>	16 weeks	Lupus	High Dose Steroids	Partial Recovery
Walsh et al. <sup>8</sup>	32 weeks	Idiopathic	High Dose Steroids	Partial Recovery
Truter et al <sup>9</sup>	36 weeks	Schistosomiasis	Esteroids And Praziquantel	Full Recovery
Dueñas-Garci et al. <sup>4</sup>	Postpartum	Epidural Anesthesia	Not reported	Maternal Death
Ariztegu et al. <sup>5</sup>	Postpartum	Epidural Anesthesia	High Dose Steroids	Full Recovery

Pregnancy and puerperium have unique hormonal, immune and mechanical changes, favoring the onset of several neurological illness. TM is little studied in this context, the inflammatory disease most studied in pregnancy is Multiple Sclerosis (MS). By making an analogy to MS cases, the postpartum period, due to changes in the immune balance, is susceptible to flares of inflammatory Th1 immunity, and if multiple sclerosis is a Th1-mediated disease, then it might follow that the increased risk of flare in disease activity postpartum may be due to a post-pregnancy shift of maternal immunity away from Th2 bias<sup>10</sup>.

Measles is a highly contagious, and preventable, viral infection characterized by fever and exanthem. Measles vaccination has markedly reduced the incidence of measles virus infection, with very

few adverse events. vaccination does not appear to cause aseptic meningitis, subacute sclerosing panencephalitis, encephalitis, and Guillain-Barre syndrome. One Chinese study reported one case of Acute disseminated encephalomyelitis 3 days after measles vaccination during an outbreak<sup>11</sup>. Even though we have not found any cases reporting transverse myelitis after measles and rubella immunization, extensive diagnostic evaluation effectively ruled out causes other than vaccination-associated TM. In theory any vaccine can cause post-vaccination TM via a possible autoimmune mechanism against the myelin sheath of the central tract.

The mainstay of treatment of transverse myelitis, in order to hasten the resolution, is with corticosteroids. Due to the rarity and diversity of presentation of the disease, there are no randomized studies with this specific population, such conduct is extrapolated from studies in patients with multiple sclerosis and case reports. Approximately one third of patients have full functional recovery, one-third have partial recovery and one-third have severe disability despite treatment<sup>6</sup>.

## CONCLUSIONS

The patient described presented with classic clinical and neuroimaging manifestations of acute transverse myelitis. Data from randomized trials to inform the treatment specifically for patients with transverse myelitis are lacking; however, on the basis of clinical experience and trials involving patients with other demyelinating diseases, high-dose corticosteroids are considered to be the first-line therapy.

There is few information on such condition in pregnancy and postpartum period, and it is considered a rare event. The puerperal period by changes that restore immune response, is susceptible to inflammatory diseases flares.

## REFERENCES

1. Goh C, Desmond PM, Phal PM. MRI in transverse myelitis. *J. Magn. Reson. Imaging.* 2014;40(6):1267–79. doi: 10.1002/jmri.24563
2. Almagro RM, Tudela MMR, Úbeda JG, Rios MHC, Venegas JJP, Guijo CC. Mielitis transversa en síndrome de Sjögren y lupus eritematoso sistémico: presentación de 3 casos. *Reumatol Clin.* 2015;11(1):41–4. doi: 10.1016/j.reuma.2014.03.008
3. Aminoff MJ, Boller F, Swaab DF. Handbook of clinical neurology. In: Flanagan EP. Autoimmune myelopathies. Rochester: Elsevier; 2016. P. 327-51
4. Dueñas-García OF, Díaz-Sotomayor M. Postparto complicado por mielitis transversa. *West Indian Med J.* 2012;61(6):643. Portuguese
5. Ariztegui NL, Marín BM, Montero RG. Acute transverse myelitis after obstetric epidural anesthesia. *Neurologia.* 2007;22(10):906-10
6. Frohman EM, Wingerchuk DM. Transverse myelitis. *N Engl J Med* 2010; 363:564-72. doi: 10.1056/NEJMcp1001112
7. Marabani M, Zoma A, Hadley D, Sturrock RD. Transverse myelitis occurring during pregnancy in a patient with systemic lupus erythematosus. *Ann Rheum Dis.* 1989;48(2):160–2
8. Walsh P, Grange C, Beale N. Anaesthetic management of an obstetric patient with idiopathic acute transverse myelitis. *Int J Obstet Anesth.* 2010;19(1):98-101. doi: 10.1016/j.ijoa.2009.04.008
9. Truter PJ, Van der Merwe JV. Transverse myelitis caused by schistosomes in pregnancy. *S Afr Med J.* 1987;71(3):184-5
10. Al-Shammri S, Rawoot P, Azizieh F, AbuQoora A, Hanna M, Saminathan TR et al. Th1/Th2 cytokine patterns and clinical profiles during and after pregnancy in women with multiple sclerosis. *J Neurol Sci.* 2004;222(1-2):21-7. doi: 10.1016/j.jns.2004.03.027
11. Shu M, Liu Q, Wang J, Ao R, Yang C, Fang G et al. Measles vaccine adverse events reported in the mass vaccination campaign of Sichuan province, China from 2007 to 2008. *Vaccine.* 2011;29(18):3507-10. doi: 10.1016/j.vaccine.2009.10.106