

ANALYSIS OF CLEANING CAPACITY OF THREE INSTRUMENTATION TECHNIQUES IN FLATTENED ROOT CANALS

● *diaphanization study* ●

*Wagner Altamirando Santana Barros de Souza**, *Paloma Souza Gonçalves***, *Luis Cardoso Rasquin****,
*Fabiola Bastos de Carvalho*****

Autor Correspondence: Fabiola Bastos de Carvalho - Email: fabiolabcarvalho@ig.com.br

* Graduado em Odontologia pela Faculdade de Odontologia da Universidade Federal da Bahia

** Especialista em Endodontia, Professora do Curso de Especialização em Endodontia do Instituto Prime de Ensino

*** Mestre e Doutor em Endodontia, Professor Adjunto da Faculdade de Odontologia da Universidade Federal da Bahia

**** Mestre em Endodontia, Doutora em Odontologia área de concentração laser, Professora Adjunta da Faculdade de Odontologia da Universidade Federal da Bahia

Abstract

The purpose of this study was to evaluate by diaphanization the cleaning ability of walls of flattened root canals prepared with three different instruments. Thirty lower incisors, which had their root canals filled with India ink after coronal access and determination of the work length, were selected. The samples were randomly divided into three groups of 10 teeth each, according to the instrument used in the preparation: Group 1 – hand files instrumentation; Group 2 – instrumentation with ProTaper Universal rotary files; Group 3 – instrumentation with iRace rotary files. After instrumentation, the teeth were diaphanized and evaluated by cleaning ability, analyzing the amount of dentin walls in which India ink was not removed. When performing the Kruskal-Wallis test ($p > 0.05$) there were not statistical significant differences between the groups, as the arithmetic average of the scores at cervical, middle and apical thirds. None of the instruments used in root canal preparation of flattened root canals was able to perform a complete cleaning of the dentin walls.

Keywords: Root Canal Preparation; Dental Pulp Cavity; Endodontics.

ANÁLISE DA CAPACIDADE DE LIMPEZA DE TRÊS TÉCNICAS DE INSTRUMENTAÇÃO EM CANAIS RADICULARES ACHATADOS

● estudo por diafanização ●

Resumo

O objetivo desse estudo foi avaliar utilizando a diafanização, a capacidade de limpeza das paredes de canais radiculares achatados preparados com três diferentes instrumentos. Foram selecionados 30 incisivos inferiores que após abertura coronária e odontometria tiveram os canais preenchidos com tinta nanquim, em seguida foram divididos aleatoriamente em três grupos de 10 dentes cada, de acordo com o instrumento utilizado no preparo: Grupo 1 – instrumentação com limas manuais; Grupo 2 – instrumentação com limas rotatórias ProTaper Universal; Grupo 3 – instrumentação com limas rotatórias iRace. Após a instrumentação, os dentes foram diafanizados e avaliados quanto a capacidade de limpeza, analisando-se a quantidade de paredes dentinárias em que a tinta nanquim não foi removida. Ao se realizar o teste de *Kruskal Wallis* ($p>0,05$) não foram observadas diferenças estatisticamente significantes entre os grupos, quanto a média aritmética dos escores nos terços cervical, médio e apical. Nenhum dos instrumentos utilizados no preparo biomecânico de canais radiculares achatados foi capaz de realizar uma completa limpeza das paredes dentinárias.

Palavras-chave: Preparo de canal radicular; Canal radicular; Endodontia.

INTRODUCTION

Endodontic therapy aims at providing an adequate biomechanical root canal preparation and its airtight sealing with an inert material, by means of root filling. To accomplish this goal, the root canal preparation stage is considered essential to the treatment success, once its purpose is the organic tissue removal, whether it is vital or necrotic, and the shaping in order to facilitate the filling materials introduction.^(1,2)

Root canal cleaning occurs through endodontic instruments mechanical action in addition to irrigating solutions and drugs physico-chemical properties, aiming at eliminating aggressors and irritants such as microorganisms, their products and pulp tissues remnants, degraded or not.⁽³⁾

Chemo-mechanical root canal preparation is the stage that requires more time in endodontic

treatment. Therefore, endodontists and dental material industries have, for a long time, concerned with creating systems that allow better root canal shaping, maintaining its original anatomy by means of an automated instrumentation, which facilitates biomechanical preparation.⁽⁴⁾ Hand instrumentation, on the other hand, enables a higher incidence of iatrogenic complications during preparation, such as canal transportation, ledges, perforations, dentin compression and presence of fractured instruments.⁽⁵⁾

Currently, rotary systems are considered safe, non-deforming nor transporting the root canal, when correctly used and indicated. Automated preparation decreases stress both in the patient and the professional. However, rotary systems shaping is not always effective, especially in flattened root canals,

since the instruments may not contact and present cutting action on all root canal walls, which is why in such cases the use of concentrated chemical solutions is especially indicated.⁽⁶⁻⁸⁾

Plotino et al.⁽⁹⁾ questioned whether the NiTi instruments flexibility allows a controlled and complete preparation of the most various anatomies found in root.

Root canal anatomical complexity difficult its cleaning and disinfection, due to endodontic instruments non-adaptation to dentin walls. The preparation of curved and flattened root canals is more complex once the instrument suffers stresses and strains imposed by the procedure, which may ultimately influence root canal treatment outcome.⁽¹⁰⁾

According to Wu et al.⁽¹¹⁾ flattened root canals buccal and lingual walls are areas of difficult access to instrumentation. Barbizam et al.⁽¹²⁾ observed by optical microscopy analysis in flattened root canals that the instruments do not contact polar areas during instrumentation. Therefore, irrigation is of fundamental importance, and its association with instrumentation is necessary to promote cleaning and disinfection of root canal systems.

Given the importance of root canal cleaning and shaping for successful endodontic treatment, the present study aims to evaluate the presence of India ink in root canal walls after the diaphanization of extracted mandibular incisors, which had their root canals prepared by three different instruments: K-type hand files (Dentsply-Maillefer-Ballaigues-Switzerland), ProTaper Universal rotary files (Dentsply Maillefer Instruments S.A.- Ballaigues - Switzerland) e iRaCe rotary files (FKG Dentaire S.A. – La-Cheaux-de Fonds – Switzerland).

METODOLOGY

The present study was submitted and approved by the Ethics in Research Committee of the Dentistry Faculty, Federal University of Bahia (protocol number 278.766).

Human mandibular incisors, extracted by periodontal disease or extensive caries, and with

complete formed apices, were selected for this study. The teeth were cleaned in order to remove any tissue debris, autoclaved and stored in saline until the moment of use.

Initially, periapical radiographs were taken both in buccolingual and mesiodistal directions for evaluations of possible calcifications in the pulp chamber and root canal, as well as the presence of more than one canal. Teeth that showed calcifications and more the one root canal were excluded from the study. Thus, 30 human mandibular incisors were selected.

The coronal access was performed with spherical diamond burs (KG Sorensen – Cotia - São Paulo - Brazil) in high speed. The working length was visually determined by introducing a size 10 Kfile (Dentsply Maillefer – Ballaigues – Switzerland) with a silicon stop into the root canal until its tip was observed at the apical foramen; 1 mm was reduced from that value.

Eventual remaining pulp was removed from the root canals through the insertion of a 15 Hedstroem (Dentsply Maillefer – Ballaigues – Switzerland) instrument to the WL with the aid of 1% sodium hypochlorite (Biodinamica – Ibiopora – PR - Brazil). Thus, the initial diameter corresponding to a 15 file to the WL for all teeth was established. The canals were then washed with 3 ml of distilled water and dried with absorbent paper points (Dentsply – Petropolis – RJ - Brazil).

The root canals were filled in with India ink (Faber Castell - Sao Carlos - SP - Brazil), previously stored within anesthetics cartridges, which was inserted into the canals with the aid of a carpule syringe and an anesthesia needle. (DFL - Rio de Janeiro – RJ - Brazil). The ink was inserted until the root canals and the pulp chamber were completely filled in and it passed through the apical foramen.

After 48 hours, time required for drying the ink, the teeth were randomly divided into three groups of 10 teeth each, according to the instrumentation technique: Group 1: K-type hand files instrumentation; Group 2: ProTaper Universal rotary files instrumentation; Group 3: iRace rotary files instrumentation.

In Group 1, shaping was performed by serial technique followed by Passive Step-back technique. Sizes 15, 20, 25 e 30 K-type hand files were used at

WL for creating the apical matrix. After its creation, the Passive Step-back technique was performed with four more instruments. In Group 2, teeth were prepared by ProTaper Universal Rotary technique, using the following operatory sequence: S1, S2, F1, F2 and F3 at WL.

In Group 3, instrumentation was performed by iRaCe Rotary, using the following operatory sequence: R1 (15.06), R2 (25.04) and R3 (30.04) at WL.

In Groups 2 and 3 an X-Smart electric engine was operated (Dentsply Maillefer – Ballaigues – Switzerland) with 250 rpm e 400 rpm speed, respectively, and torque suggested by each file manufacturer. A 0.30 mm apical matrix diameter was standardized for all groups.

During instrumentation, 1 ml of 1% sodium hypochlorite was used, in association with Endo-PTC (Compounding Pharmacy), as each instrument was replaced. By the time the preparation was finished, the smear layer was removed with the aid of 0.1 ml of 17 % EDTA (Iodontosul, Porto Alegre - RS - Brazil), agitated with the aid of an instrument for 1 minute and removed with 1 ml of 1% sodium hypochlorite. The final rinse of the root canal was performed with 0.5 ml of a detergent solution (Iodontosul - Porto Alegre - RS - Brazil).

After instrumentation root canals were dried with size 30 absorbent paper points (Dentsply – Petropolis – RJ - Brazil).

For the diaphanization process, teeth were individually stored within glass recipients and

decalcified with muriatic (Muriac - Salvador – BA - Brazil) during approximately 72 hours, until a needle transpassing through the root could be observed. Once verified decalcification, teeth were washed in running water for 4 hours, and then submitted to dehydration phase with ethyl alcohol in its various concentrations: 80% (for 12 hours), 90% (for 2 hours) e 100% (for 3 hours). After drying, the samples were placed in methyl salicylate to achieve transparency.

The diaphanized teeth were evaluated by using the light box and a SONY DSC-HX1 camera (Sony Brasil – São Paulo – SP - Brazil) at an 8X increase. The presence of India Ink at dentin walls of each third of the root canal was evaluated according to the following score:

- 0 – absence of ink on dentin walls;
- 1 – presence of ink on one wall;
- 2 - presence of ink on two walls;
- 3 - presence of ink on three walls;
- 4 - presence of ink on four walls.

The arithmetic average of the scores was statistically analyzed by Kuskal Wallis test with a 5% significance level using the BioEstat 5.0 software.

RESULTS

The root canal cleaning was analyzed by observing the ink removal from dentin walls in each third by means of scores, and the lower the score, the better the cleaning of the root canal (Figures 1-3).



Figure 1- Group 1 (hand files) tooth, with scores 0 in the cervical third, 1 in the middle and apical thirds

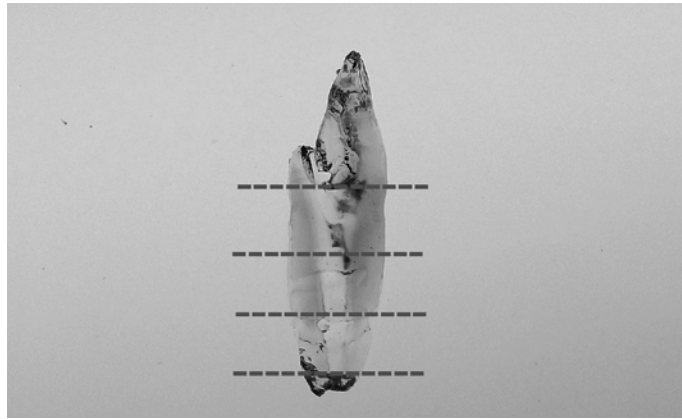


Figure 2 - Group 2 (ProTaper Universal) tooth, with score 0 in the three thirds.

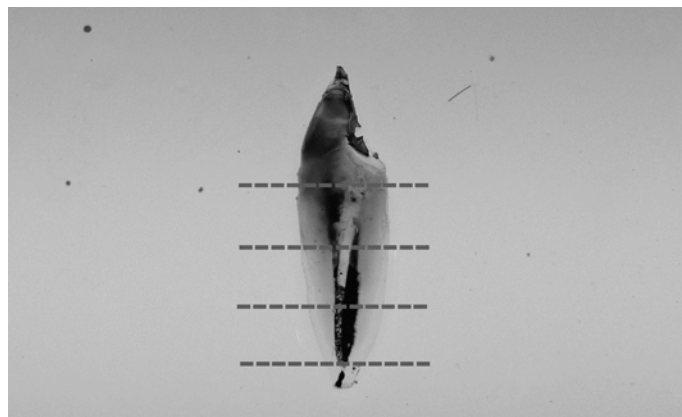


Figure 3 - Group 3 (iRace) tooth, with score 2 in the cervical third and 4 in middle and apical thirds

Figure 4 shows the scores frequency for each third of the evaluated groups.

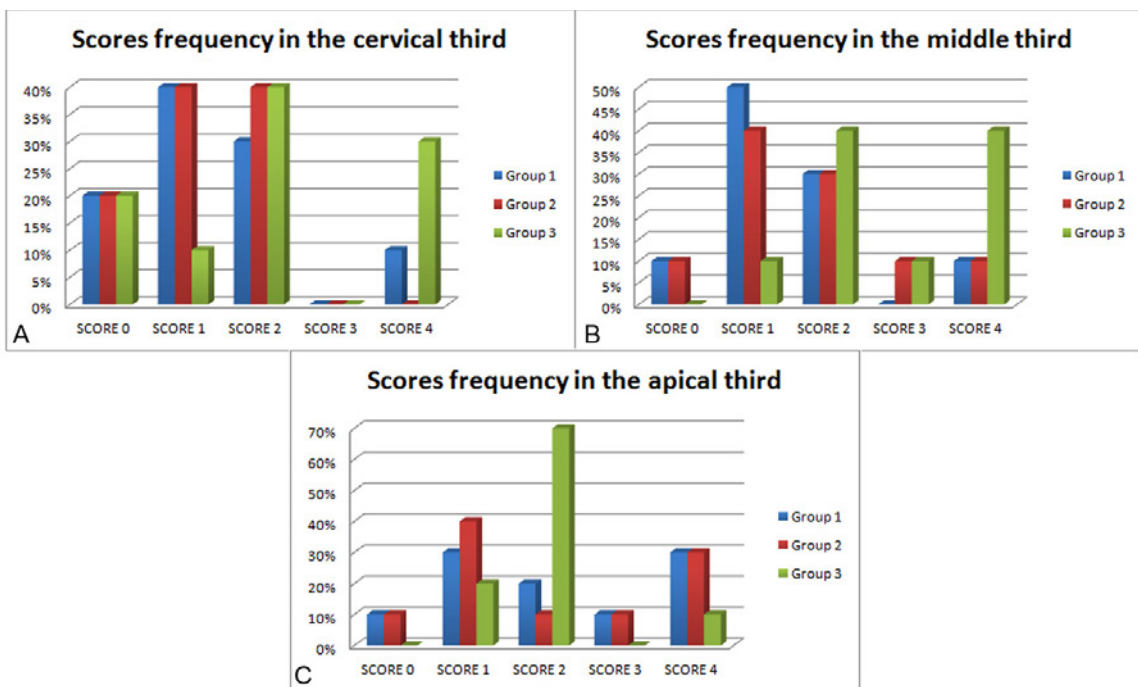


Figure 4 - Scores frequency of the 3 groups in cervical (A), middle (B) and apical (C) thirds

The averages of the scores obtained in each root canal third are shown in Table 1. During instrumen-

tation there were no files fractures.

Table 1 - Scores averages for each root canal third of the evaluated groups

GROUP	CERVICAL	MIDDLE	APICAL
GROUP 1 (Hand files)	1,4	1,5	2,2
GROUP 2 (ProTaper Universal)	1,2	1,7	2,1
GROUP 3 (iRaCe)	2,1	2,8	2,0

Kruskal Wallis ($p=0.2019$).

In general, Group 2, which ProTaper Universal System instrumentation was performed, resulted in cleaner walls, followed by Group 1 (hand files instrumentation) and Group 3 (iRaCe system). However, there was no statistical difference among the groups as to the average of the scores in the cervical, middle and apical thirds (Kruskal Wallis $p>0.05$).

DISCUSSION

The root canal preparation aims to achieve the correct cleaning and disinfection of the canals systems, as well as at obtaining an uniform and continuous conical shape, maintaining the foramen's original spatial position. Nevertheless, anatomical diversity, such as those found in flattened canals, may hinder therapy, often leading to failure.⁽¹³⁻¹⁶⁾

Flattened or oval canals studies use the mesial root of molars^(17,18) or mandibular incisors.^(5,10,19,20) Extracted mandibular incisors were used in this study by having a pronounced flattening on the mesiodistal direction, which can generate a second canal lingually located to the main one, as well as the occurrence of severely flattened canals, with elongated cross-section, being the biggest diameter on the buco-lingual direction.⁽¹³⁾ Mandibular incisors with more than one root canal were excluded and only the ones with mesiodistal flattening were used.

To evaluate the instrumentation techniques as for their cleaning ability, the present study used the methodology that makes use of dentin walls coloring, similar to Grecca⁽²¹⁾ and Sipert et al.⁽¹⁷⁾ studies. It is important to mention that the dye (Indian Ink) used

is water insoluble, which made each instrumentation technique the only responsible for the dye removal.

The results analysis showed that Group 2 (ProTaper Universal) achieved a better cleaning in the cervical third, although this difference was not statistically significant when compared to the other groups. This result corroborates Martini et al.⁽²²⁾ study, which tested four root canal preparation systems and ProTaper system presented the best results, once they are nickel-titanium rotary instruments endowed with extreme flexibility e multiple tapers, especially in S1 and S2 instruments, intended for the preparation of the cervical and middle thirds, eliminating more efficiently dentin interferences on these areas.

Regarding to the other groups, Group 1 (hand file instrumentation) achieved better cleaning in the middle third, while Group 3 (iRaCe) showed better cleaning in the apical third, although this difference has no statistical significance. A better cleaning was expected from the rotary techniques, once these systems present superior tapers compared to ISO hand instruments, providing a suitable enlargement of the cervical and middle thirds, and thus facilitating the preparation of the apical third.⁽²³⁾ The brushing motion is the one suggested for rotary files use, in which the instrument is guided against the canal lateral walls and pulled in coronal direction.⁽²⁴⁾ In the present study, even though brushing motion was used in Groups 2 and 3, the presence of dye was observed in dentin walls.

In Group 1 (hand file instrumentation), linear motion was applied to the files, and even so dye was observed in dentin walls, similar to Wu et al.⁽²⁵⁾ study,

which by evaluating two hand file instrumentation techniques in mandibular incisors, observed that both balanced-force and circumferential movements left large areas of the root canal without instrumentation.

Barato-Filho et al.⁽²⁶⁾ evaluated the canal preparation in human mandibular central incisors using ProTaper system, and as a result a better preparation was achieved by using F₁, F₂ and F₃ instruments in apical preparation in aid with 2.5% sodium hypochlorite. This paper results show that even when using instruments with greater taper than the ISO standard (Group 2 – F₂ 30/09; Group 3 – 30/04) in the apical third, there was dye permanence on the root canal walls.

The root canal apical third is considered a critical area regarding to cleaning, shaping and filling.⁽²⁷⁾ This fact can be noticed in our study, where the higher scores, ie, the higher number of walls with dye presence, was found in the apical third (Table 1).

Grecca et al.⁽¹⁰⁾ evaluated rotary, hand file and ultrasonic instrumentation techniques in flattened canals. After statistical analysis, the authors concluded that there was no significant difference among the groups and that none of them had completely removed the dyed areas. This is in agreement with the results obtained in our study.

However, Schirmermeister et al.,⁽²⁸⁾ while comparing ProTaper system with four other instruments in the preparation of simulated root canals, found that the RaCe system (by using the following files sequence: 40/10; 35/08; 30/06; 25/04 crown down direction, and 25/02; 30/02 at WL) presented the best canal preparation. This was not observed in our study, which showed no statistical difference among the used techniques.

According to Grecca,⁽²¹⁾ the more complex the root canal anatomy is, the greater number of instruments should be used, being the larger tapers in the cervical and middle thirds and the minor in the apical third. The iRaCe system recommends using only 3 (15/06; 25/04; 30/04), which may have influenced the negative results presented by this system.

In general, literature shows that there is still no technique that prepares root canals with mesio-distal flattening in their entirety. The circular preparations provided by instrumentation, whether rotary or manual, do not cover all root canal walls, once they

promote the circular preparation that corresponds to the instrument cross-section, which leaves the remaining material cleaning to the auxiliary chemical solutions, which may lead to therapy failure.⁽²⁹⁾ That can be proved by the present study results, where no technique was able to promote the complete cleanliness of the dentin walls.

The challenge in promoting an adequate cleaning to the flattened root canals has already been reported in the scientific literature, as debris were found after biomechanical preparation, especially in isthmuses and polar areas.^(19, 28-30) According to the present study, more than 76.4% of the walls that remained dirty after preparation were buccal or lingual walls, demonstrating the challenge of the instrumentation of these areas in flattened canals.

It could be observed that, despite technological advances related to root canals preparation, the anatomical complexity is still one of the limiting factors that should be considered in choosing instrumentation protocol. According to the literature and the results found in the present study, the search for techniques and instruments that provide a better cleaning of the the flattened root canal system is necessary, once none of the evaluated techniques has successfully cleaned the dentin walls.

CONCLUSION

There was no statistical difference ($p > 0.05$) among the preparation techniques used, as for the ability of removing India Ink in the cervical, middle and apical thirds. According to the methodology, none of the techniques used in the flattened root canals biomechanical preparation was capable of accomplishing a complete cleaning of the dentin walls, although on average ProTaper Universal instruments have shown a greater number of clean walls, followed by hand files and iRaCe.

REFERENCES

1. Sydney GB, Batista A, Deonizio MD. Radicular access. *Robrac*. 2008;17(43):1-12.

2. De Martin G, Azeredo RA. Análise do preparo de canais radiculares utilizando-se a diafanização. *Rev. odontol. UNESP*. 2014;43(2):111-118.
3. Hulsmann M, Heckendorff M, Lennon A. Chelating agents in root canal treatment: mode of action and indications for their use. *Int Endod J*. 2003;36(12):810-30.
4. Semaan FS, Fagundes FS, Haragushiku G, Leonardi DP, Baratto-Filho F. Mechanized endodontic: the evolution of continuous rotary systems: [review]. *RSBO*. 2009;6(3):297-309.
5. Gonçalves SB, Brosco VH, Bramante CM. Comparative analysis of rotatory (GT) and manual root canal preparation and association of both techniques in instrumentation of flattened root canals. *J Appl Oral Sci*. 2003;11(1):35-9.
6. Baratto-Filho F, Vanni JR, Maia SMAS, Sousa-Neto MD, Leonardi DP. Shaping ability of ProTaper instruments in flattened root canals. *Perspect Oral Sci*. 2009;1:25-9.
7. Amadeu SCG, Cunha RS, Bueno CES, Abe FC, Martin AS. Analysis of the preparation obtained by three techniques of root canal instrumentation using computed tomography. *RGO*. 2013;61(4):535-541.
8. Nekoofar MH, Sheykhrezae MS, Meraji N, Jamee A, Shirvani A, Jamee J et al. Comparison of the effect of root canal preparation by using waveone and protaper on postoperative pain: A randomized clinical trial. *J Endod*. 2015;41(5):575-8
9. Plotino G, Grande NM, Melo CM, Bahia MG, Testarelli L, Gambarini G. Cyclic fatigue of NiTi rotary instruments in a simulated apical abrupt curvature. *Int Endod J*. 2010; 43(3):226-30.
10. Grecca FS, Garcia RB, Bramante CM, Moraes IG de, Bernardineli N. A quantitative analysis of rotary, ultrasonic and manual techniques to treat proximally flattened root canals. *J Appl Oral Sci*. 2007;15(2):89-93.
11. Wu MK, R'oris A, Barkis D, Wesselink PR. Prevalence and extend of long oval canals in the apical third. *Oral Surg Oral Med Oral Pathol Oral Radiol Endod*. 2000; 89(6):739-43.
12. Barbizam JVB, Fariniuk LF, Marchesan MA, Pecora JD, Sousa-Neto MD. Effectiveness of Manual and Rotary Instrumentation Techniques for Cleaning Flattened Root Canals. *J Endod*. 2001;28(5):365-66.
13. Pires LB, Albergaria SJ, Fagundes Tomazinho FS, Tomazinho LF. Radiographic evaluation of apical deviation of curved root canals after the use of manual and rotary instrumentation. *RSBO*. 2009;6(3):279-85.
14. Rasquin LC, Carvalho FB, Lima RKP. In vitro evaluation of root canal preparation using oscillatory and Rotary systems in flattened root canals. *J. appl Oral Sci*. 2007;15:65-9.
15. Silva JA, Caetano CHMS, Alencar AHG, Estrela CRA, Borges AH, Decurcio DA et al. A critical analysis of the sanitization strategies on root canal cleaning. *Stomatos*. 2013;19(37):48-59.
16. Silva PAA, Guimarães BM, Perochena AC, Pérez CAF, Cavenag BC, Duarte MAH et al. Comparação dos debris produzidos após instrumentação pelos sistemas waveone e protaper em canais mesiais de molares inferiores. *ROBRAC*. 2012;21(58):560-63.
17. Sipert CR, Hussne RP, Nishiyama CK. Comparison of the cleaning efficacy of the FKG Race system and hand instrument in molar root canal. *J Appl Oral Sci*. 2006;14(1):6-9.
18. Gonçalves LCO, Junior ECS, Frota MF, Marques AAF, Garcia LFR. Morphometrical analysis of cleaning capacity of a hybrid instrumentation in mesial flattened root canals. *Aust Endod J*. 2011;37(3):99-104.
19. Interliche R, Marchesan MA, Silva SRC, Pécora JD, Silva-Sousa YTC, Sousa-Neto MD. Influence of Hero Apical instruments on cleaning ovoid-shaped root canals. *Braz Oral Res*. 2011;25(4):314-8.
20. Sasaki EW, Versiani MA, Perez DE, Sousa-Neto MD, Silva-Sousa YT, Silva RG. Ex vivo analysis of the debris remaining in flattened root canals of vital and nonvital teeth after biomechanical preparation with Ni-Ti rotary instruments. *Braz Dent J*. 2006;17(3):233-6.
21. Grecca FS. Avaliação da eficácia dos métodos de instrumentação rotatória (sistema K3 e Protaper), ultra-som e manual na remoção de corante aderido às paredes de canais radiculares com achatamento proximal. *Estudo*

- “in vitro” (tese). Bauru (SP): Faculdade de Odontologia de Bauru; 2003.
22. Martini GR, Vanni JR, Bona AD, Lazaretti DA. The influence of different methods of cervical magnifying in the attainment of the length of work in first mesio-vestibular canals tests of superior molar. *RSBO*. 2007;4(2):7-11.
 23. Pécora JD, Capelli A. Técnica mecanizada para preparo dos canais radiculares- Protaper Plus. [article online]. School of Dentistry of Ribeirão Preto, University of São Paulo. 2004. [Accessed on 2013 April 27]. Available at http://www.forp.usp.br/restauradora/rotatorios/protaper_plus/protaper_plus.pdf.
 24. Lopes HP, Souza LC, Vieira VTL, Silveira AMV, Vieira MVB, Elias CN. Fratura dos instrumentos endodônticos. Recomendações clínicas. *Rev Bras Odontol*. 2011;68(2):152-6.
 25. Wu MK, Sluis VLWM, Wesselink PR. The capability of two hand instrumentation techniques to remove the inner layer of dentine in oval canals. *Int Endod J*. 2003;36(3):218-24.
 26. Baratto-Filho F, Leonardi DP, Zielak JC, Vanni JR, Sayão-Maia SMA, Sousa-Neto MD. Influence of protaper finishing files and sodium hypochlorite on cleaning and shaping of mandibular central incisors - A histological analysis. *J Appl Oral Sci*. 2009;17(3):229-33.
 27. Ritt AS, Bucu J, Wagner MH, Rosa RA, Vier-Pelisser FV, S6 MVR. Effectiveness evaluation of manual x rotary instrumentation during endodontic retreatment in root canals filled with gutta-percha and calcium hydroxide based-sealer. *RFO UPF*. 2012;17(1):55-59.
 28. Schirrmeister JF, Wrbas KT, Schneider FH, Altenburger MJ, Hellwig E. Effectiveness of a hand file and three nickel-titanium rotary instruments for removing gutta-percha in curved root canals during retreatment. *Oral Surg Oral Med Oral Pathol Oral Radiol Endod*. 2006;101(4):542-7.
 29. Williamson AE, Sandor AJ, Justman BC. A comparison of three nickel titanium rotary systems. EndoSequence, ProTaper universal, and ProFile GT, for canal-cleaning ability. *J Endod*. 2009; 35(1):107-109.
 30. Taha NA, Ozawa T, Messer HH. Comparison of three techniques for preparing oval-shaped root canals. *J Endod*. 2010;36(3):532-35.